

A Evaluation of Gastrointestinal Causes of Recurrent Abdominal Pain in Children

¹IQTADAR SEERAT,²MUHAMMAD ARSHAD ALVI

¹Consultant Paediatric Gastroenterology, Hepatology & Nutrition, KFSH&RC, Jeddah, Saudi Arabia,

²Assistant Consultant, Paediatric Gastroenterology, Hepatology & Nutrition, KFSH&RC, Jeddah, Saudi Arabia.

Correspondence: Dr Iqtadar Seerat, Consultant Paediatric Gastroenterology, Hepatology & Nutrition, KFSH&RC, Jeddah, Saudi Arabia. Contact No: 00966559629265. Email: iseerat@hotmail.com

ABSTRACT

Aims & Objective: To evaluate Etiology of recurrent abdominal pain in children with and without alarm symptoms

Study Design: Retrospective study.

Place and Duration of Study: This retrospective study was conducted for the time period starting from February, 2016- February, 2017 at the department of Paediatric Gastroenterology, Hepatology & Nutrition, KFSH&RC, Jeddah, Saudi Arabia.

Materials and Methods: 25 children were recruited in this study with history of recurrent abdominal pain. Out of 25 there were 17 children with alarm symptoms and 8 without alarm symptoms. The referrals were made from different specialities of our department and also from a number of local hospitals outside Jeddah.

Results: Out of 17 patients with RAP and alarm symptoms there were 3 cases (17.5%) of reflux oesophagitis, 1 case (5.8%) of eosinophilic oesophagitis, 10 cases (59%) of Crohn's disease, 1 case (5.8%) of chronic gastritis and 2 cases (11.7%) of irritable bowel syndrome were diagnosed. In 8 children without alarm symptoms there were 2 cases (25%) of H. Pylori gastritis, 2 cases (25%) of Crohn's disease and 1 case (12.5%) of coeliac disease. The diagnosis of irritable bowel syndrome was made in rest of 3 patients (37.5%).

Conclusion: Majority of children with alarm symptoms were diagnosed with organic diseases. Children with ongoing recurrent abdominal pain without alarm symptoms were also found to have organic causes. Therefore children of recurrent abdominal pain even without alarm symptoms should also be investigated and managed by Paediatric gastroenterology team due to high prevalence of underlying organic diseases to avoid any delay.

Key Words: Recurrent abdominal pain (RAP), alarm symptoms, organic causes, Non-organic causes

INTRODUCTION

The commonly accepted definition of RAP is at least 3 episodes of pain over a period of 3 months, severe enough to affect the normal routine activities.¹ Recurrent abdominal pain in children could be very difficult and challenging for paediatricians to manage.

Due to the availability of innovative investigations and better understanding of the pathogenesis of abdominal pain, a whole range of organic diseases have been identified in children. A few symptoms such as pain away from the umbilicus, vomiting, rectal bleeding, night pain and abnormal laboratory findings suggest organic pathology. It is commonly stated that the most common cause of recurrent abdominal pain without alarm symptoms in children is non

organic.² But a few reports have revealed that children even without alarm symptoms could have underlying organic diseases. Therefore it is also important to investigate this group of patients before labelling them with functional disorders.^{3,4}

Hence our main purpose is to investigate children of recurrent abdominal pain not only with alarm symptoms but also without alarm symptoms to diagnose underlying GI causes which could be present in the latter group.

MATERIALS & METHODS

This retrospective study was conducted for the time period starting from February, 2016- February, 2017 at the department of Paediatric Gastroenterology, Hepatology & Nutrition,

KFSH&RC, Jeddah, Saudi Arabia. 25 children were recruited in this study.

A spread sheet was prepared to collect data of this study. Data was collected from the hospital computerised data system. It was collected for children of recurrent abdominal pain with and without alarm symptoms and then was compared to each other. Data was presented in percentages and frequencies in form of graphs and a table. Children from the age of 4-13 years were recruited.

RESULTS

Amongst 25 children there were 13 boys and 12 girls. 14(56%) children were between 4-8 years, 7(28%) between 9-12 years and 4 (16%) were between 13-14 years.

Out of 17 patients with RAP and alarm symptoms there were 3 cases (17.5%) of reflux oesophagitis, 1 case (5.8%) of eosinophilicoesophagitis, 10 cases (59%) of Crohn's disease, 1 case (5.8%) of chronic gastritis

and 2 cases (11.7%) of irritable bowel syndrome. In 8 children without alarm symptoms there were 2 cases (25%) of H.Pylori gastritis, 2 cases (25%) of Crohn's disease and 1 case (12.5%) of coeliac disease. The diagnosis of irritable bowel syndrome was made in rest of 3 patients (37.5%). With regards to alarm symptoms 5 children (20%) presented with vomiting, 8 (32%) with diarrhoea, 3 (12%) with weight loss, 3 (12%) with PR bleeding and 1(4%) with haematemesis as shown in table 1. Children presented with one or more than one alarm symptoms.

Table 1: Alarm symptoms in patients with RAP

Alarm Symptoms	Number of patients
Vomiting	5
Diarrhoea	8
Weight Loss	3
PR bleeding	3
Haematemesis	1

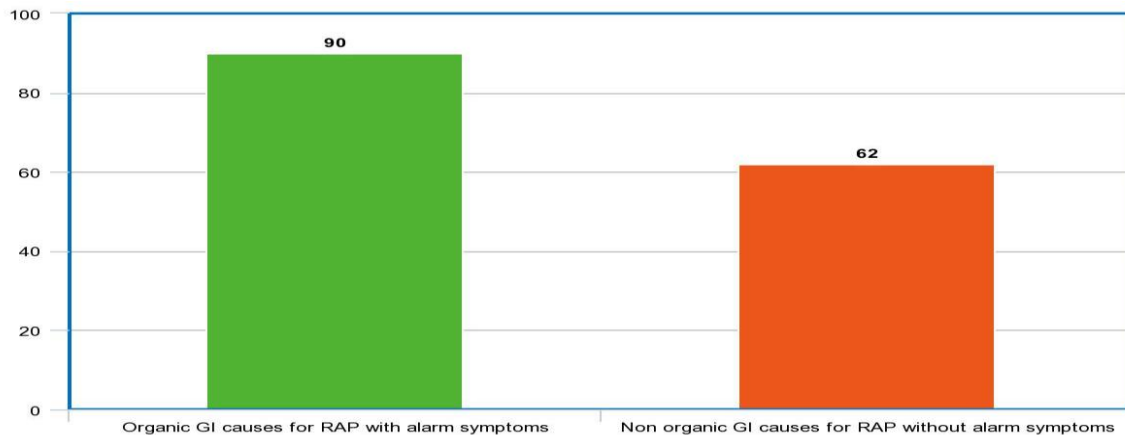


Figure 1: Comparison of organic and non organic GI causes for RAP with and without alarm symptoms

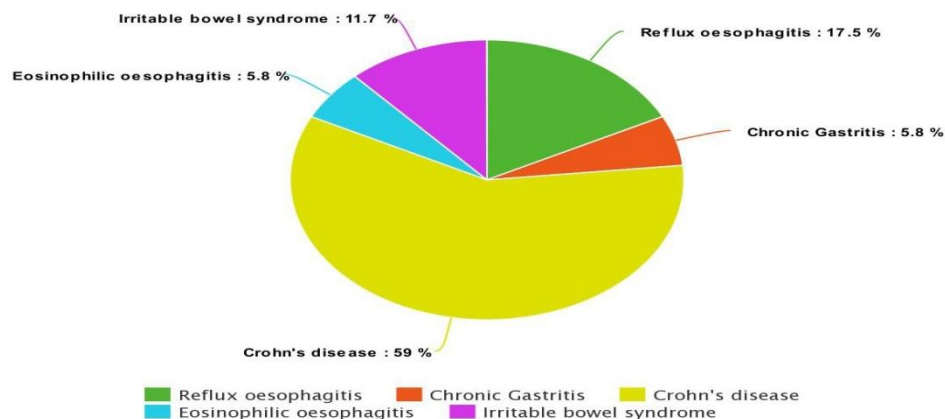


Figure 2: Organic and non organic GI causes for children with alarm symptoms

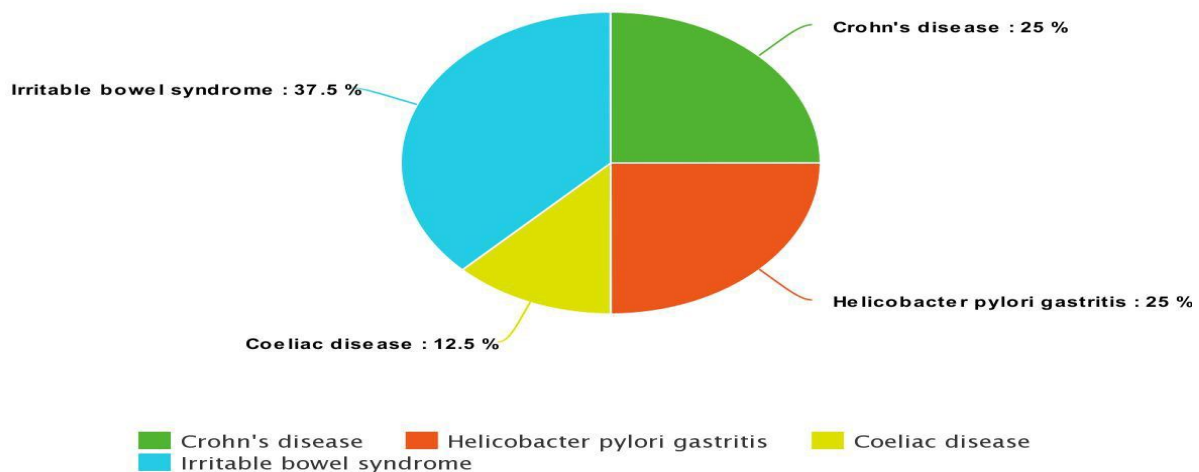


Figure 3: Organic and non organic GI causes for children without alarm symptoms

DISCUSSION

It is generally stated that the aetiology of RAP in children remains non organic if the location of pain is away from the periumbilical area. But we have observed in our study that young children find difficult to localise the pain. Therefore we decided to investigate all children presenting to us with RAP with and without alarm symptoms. They were investigated first with routine laboratory investigations. In majority of patients relating to both groups (with and without alarm symptoms) the preliminary work up was unremarkable. Therefore due to ongoing symptoms all children with and without alarm symptoms underwent upper GI endoscopy and colonoscopy.

With help of these procedures we were able to determine the gastrointestinal causes of RAP in both groups of patients. The esophagogastroduodenoscopy was helpful in confirming diseases like refluxoesophagitis, celiac disease, eosinophilic oesophagitis, helicobacter pylori (HP) gastritis. While colonoscopy was useful in confirming Crohn's disease.

Fifty percent of our patients were females and this observation was not dissimilar to other reports mentioned in the literature.^{5,6,7}

A study by Motamed F, fifty seven percent of children were found to have underlying organic aetiology for recurrent abdominal pain, while in various reports the prevalence of organic diseases ranges between twenty three percent and eighty percent in different communities.⁸

But our study revealed that 90 % of patients with RAP and alarm symptoms were not only diagnosed with underlying GI diseases but children even without alarm symptoms have had organic GI diseases (62%). In Motamed F's study not even a single case of Crohn's disease was diagnosed but in our study 10 children were confirmed with Crohn's disease. This may be due to the fact that the world wide incidence of Crohn's disease is on the rise.^{9,10,11} Although a higher prevalence of HP was reported in developing countries as a cause of RAP in children, however, in an Iranian study, no connection was found between recurrent abdominal pain and helicobacter pylori peptic acid disease.^{12,13} In our study only 2 cases of HP were found. In the literature it has also been mentioned that children presenting with RAP even without alarm symptoms should be investigated as the treatable causes could be picked up especially with help of upper GI endoscopy and colonoscopy.^{14,15,16,17,18} In one study reported by Tolone C, 57% of children with RAP without alarm symptoms have had an underlying organic disease.¹⁹ In that study 22.6% and 20.2% of patients were diagnosed with lactose intolerance and coeliac disease respectively. Our study showed that 62% of patients without alarm symptoms had not only organic GI diseases but also the spectrum of diseases was different. There were 25% of children with HP gastritis, 25% with Crohn's disease and 12.5% with coeliac disease.

CONCLUSION

Majority of children with alarm symptoms were diagnosed with organic diseases. Children with ongoing recurrent abdominal pain without alarm symptoms were also found to have organic causes. Therefore children of recurrent abdominal pain even without alarm symptoms should be investigated and managed by Paediatric gastroenterology team due to high prevalence of underlying organic diseases to avoid any delay. We recommend larger studies to be done in the future to support and strengthen our findings.

REFERENCES

- Berger MY, Gieteling MJ, Benninga MA; Chronic abdominal pain in children. *BMJ*. 2007 May 12; 334(7601):997-1002.
- Liebman WM. Recurrent abdominal pain in children: a retrospective survey of 119 patients. *Clin Pediatr*. 1978; 17(2):149-53.
- Gomez- Suarez R. Difficulties in the Diagnosis and Management of Functional or Recurrent Abdominal Pain in Children. *Pediatr Ann*. 2016 Nov, 1 45(11):388-93.
- Seng Hock Quak. Recurrent abdominal pain in children: a clinical approach. *Singapore Med J*. 2015 Mar; 56(3): 125–128
- Stordal K, Nygaard EA, Bentsen BS. Recurrent abdominal pain: a five-year follow-up study. *Acta Paediatr*. 2005; 94(2):234–6.
- Buch NA, Ahmad SM, Ahmed SZ, et al. Recurrent abdominal pain in children. *Indian Pediatr*. 2002; 39(9):830–4.
- Devanarayana NM, Rajindrajith S, De Silva HJ. Recurrent abdominal pain in children. *Indian Pediatr*. 2009; 46(5):389–99
- Motamed F, Mohsenipour R, Seifirad S, Yusefi A, Farahmand F, Khodadad A, Falahi G, Najafi M. Red flags of organic recurrent abdominal pain in children: study on 100 subjects. *Iran J Pediatr*. 2012 Dec; 22(4):457-62.
- Zayyani NR, Malaty HM, Graham DY. Increasing Incidence of Crohn's Disease with Familial Clustering in the Kingdom of Bahrain: A 25-Year Population-based Study. *Inflamm Bowel Dis*. 2017 Feb; 23(2):304-309.
- Kugathasan S, Judd RH, Hoffmann RG, et al. Epidemiologic and clinical characteristics of children with newly diagnosed inflammatory bowel disease in Wisconsin: a state wide population-based study. *J Pediatr*. 2003 Oct. 143(4):525-31.
- Griffiths AM, Buller HB. Inflammatory bowel diseases. Walker WA, Durie Peds. *Textbook of Pediatric Gastrointestinal Diseases*. 3rd ed. 2000.
- McCallion WA, Bailie AG, Ardill JE, et al. *Helicobacter pylori*, hypergastrinaemia, and recurrent abdominal pain in children. *J Pediatr Surg*. 1995; 30(3):427–9.
- Masoodpoor N, Darakhshan, Sheikhvatan M. *Helicobacter pylori* infection in Iranian children with recurrent abdominal pain. *Trop Gastroenterol*. 2008; 29(4):221–3.
- Thomson M, Tringali A, Landi R, Dumonceau JM, Tavares M, Amil-Dias J, et al. Pediatric Gastrointestinal Endoscopy: European Society of Pediatric Gastroenterology Hepatology and Nutrition (ESPGHAN) and European Society of Gastrointestinal Endoscopy (ESGE) Guidelines. *J Pediatr Gastroenterol Nutr*. 2016 Sep.
- El-Mouzani MI, Al-Mofleh IA, Abdullah AM, et al. Indications and yield of upper gastrointestinal endoscopy in children. *Saudi Med J*. 2004; 25(9):1223-5.
- Mudawi HM, El Tahir MA, Suleiman SH, Eltaybe NH, Gamer NM, Abdalla FA, Ibrahim SZE. Pediatric gastrointestinal endoscopy: experience in a Sudanese university hospital. *Mediterr Health J*. 2009 Jul-Aug; 15(4):1027-31.
- Castellaneta SP, Afzal NA, Greenberg M, Deere H, Davies S, Murch S, et al. Diagnostic role of upper gastrointestinal endoscopy in pediatric inflammatory bowel disease. *Pediatr Gastroenterol Nutr*. 2004 Sep; 39 (3):257-61.
- Cameron DJ. Upper and lower gastrointestinal endoscopy in children and adolescents with Crohn's disease: a prospective study. *J Gastroenterol Hepatol*. 1991 Jul-Aug; 6(4):355.
- Tolone C, Pellino V, Piccirillo M, Letizia M, Belfiore I, Tolone S. Recurrent abdominal pain in children: underlying pathologies in absence of alarm symptoms and signs in a tertiary center. *Minerva Pediatr*. 2016 Jan 8.