

Appendicular Stump Disinfection Using Povidone- iodine Swab Compared with Electrocautery; which one is more effective?

¹QAMAR ASHFAQ AHMAD, ²MUHAMMAD ZEESHAN SARWAR, ³MAH JABEEN MUNEERA, ⁴WAQAS LATIF, ⁵ASAD AIZAZ CHATHA, ⁶KHADIJA WAHEED

Assistant Professor of Surgery, SIMS/ Services Hospital Lahore¹, Assistant Professor Surgery, KEMU/ Mayo Hospital Lahore², Associate Professor of Anatomy, KEMU Lahore³, Biostatistics Data Analyst, Msc (Stat), University of Health Sciences Lahore⁴, Assistant Professor of Maxillofacial Surgery, KEMU/Mayo Hospital, Lahore⁵, Assistant Professor of Gynaecology, Lady Aitchison Hospital, Lahore⁶.

Corresponding Author: Dr. Qamar Ashfaq Ahmad, Assistant Professor of Surgery, Services institute of Medical Sciences/ Services Hospital Lahore. Email: qamarsurg@yahoo.com

ABSTRACT

Objective: To evaluate the effectiveness of povidone-iodine swab versus electrocautery to disinfect appendicular stump.

Methods: A randomized controlled trial was conducted in Services Institute of Medical Sciences, Lahore, with a sample size of 40 patients from 1st Dec 2012 to 31st August 2013. Random allocation was done into two equal groups. After cutting appendix, a culture swab was taken from the appendix stump. Electrocautery was used to disinfect appendicular stump in group A while, 10% povidone-iodine was used in group B. A second culture swab was taken from stump after five minutes. Absence of growth on the second culture was considered as effective therapy.

Results: Out of total 40 patients, 27 (67%) were males and 13 (33%) were females. Mean age of the patients was 25.6 years. Electrocautery was effective in 100% while Povidone-Iodine was effective in 60% cases ($p < 0.05$). Wound infections were reported in 15% of the cases in electrocautery group and 20% in povidone-iodine group. While assessing possible relationship between wound infection and effective appendix stump disinfection. Out of 32 (20 in Group A and 12 in Group B) cases who were "effectively treated" as shown by negative culture reports after application of either intervention (cautery/ povidone-iodine), 4 (12%) cases developed wound infection. Whereas 3 out of 8 (All in Group B) (37%) patients in 'In effectively treated' group developed wound infection. Relationship between effectiveness of the treatment and wound infection could not reach to a statistically significance level. ($p = 0.096$)

Conclusion: Electrocautery is better option in disinfecting appendix stump as compared to Povidone-Iodine swab.

Keywords: Appendix, Povidone-Iodine, Electro coagulation, Disinfection

INTRODUCTION

Appendectomy is the most commonly performed operation in the surgical emergency. The life time risk of developing acute appendicitis is 8.6% for males and 6.7% for females⁽¹⁾. Emergency appendectomy is the standard treatment with approximately 400,000 appendectomies being done annually in Pakistan⁽²⁾. Appendectomy is a clean-contaminated operation, as the stump of appendix is lined by the highly contaminated flora of the colon⁽³⁾. So the stump should be treated in a way to keep the spillage of septic material to minimum level⁽⁴⁾. Over the years, appendicular stump had been dealt in many ways to avoid septic complications. In the past, appendicular stump invagination was attempted with no definite advantage⁽⁵⁾. Later on, carbolic acid and phenol

were used for cauterization of appendicular mucosa with variable results⁽⁶⁾. Currently, electrocautery using monopolar or bipolar cautery is being widely used and is becoming the gold standard technique to deal with the contaminated colonic mucosa on appendicular stump⁽⁷⁾. As electrocautery can cause lateral thermal damage to the caecum, application of povidone-iodine to disinfect the appendicular stump came in vogue⁽⁸⁾. This conventional practice of applying povidone-iodine on appendix stump, although recommended in literature, was not backed up by scientific data to clarify its use on appendix stump. There is scarce data available to address this issue. The usual practice is surgeon's own preference. Therefore, current study was conducted to evaluate the effectiveness of povidone-iodine as compared to

electrocautery for disinfecting appendix stump and to find out wound infection using either intervention.

PATIENTS AND METHODS

This randomized controlled trial was conducted in surgical unit III, Services Institute of Medical Sciences, Lahore, Pakistan from 1st Dec 2012 to 31th August 2013. A pilot study was conducted earlier to check the effectiveness of povidone-iodine application after appendectomy. The results showed electrocautery to be 100% effective in comparison to povidone-iodine (60%) in disinfecting appendicular stump. Considering use of electrocautery as widely accepted surgical practice in the literature^(9,10,11,12) along with the results of pilot study, the electrocautery was regarded as the 'control' (Group A) in this study. A sample size of 40 (20 in each group) was calculated by keeping (alpha) level of significance 5%, power (1-beta) 90% and, a decrease in the primary outcome measure from 100% in the control group (electrocautery) to 60% in the experimental group (povidone-iodine). All patients who presented in surgical emergency with pain right iliac fossa were evaluated by the consultant surgeon. Clinically diagnosed acute appendicitis patients, who underwent open appendectomy, were included in the study. Patients with age less than 8 years and more than 65 years, complicated acute appendicitis and those already taking antibiotics for 3 to 4 days were excluded from the study. Patients in which 1st sample from appendicular stump did not reveal any bacterial growth were also excluded from the study. Study was approved by Institutional Ethical Review Committee. A written informed consent was obtained from all the participants. Patients were randomly divided into group A or B by computer generated random number. All patients received prophylactic antibiotics (Inj. Ceftriaxone 1 g and Inj. Metronidazole 500mg) at the time of skin incision. Only aerobic culture facility was available in our institution so only aerobic culture was taken. After cutting appendix, a culture swab (sample 1) was taken from appendicular stump, thoroughly wiping off its cut edge till it becomes moist. The culture swab was placed straight in "Amies transport media with charcoal" and sent to the laboratory as soon as possible. The transport media was kept at 25-30° C and then delivered to the laboratory, in case there was delay of few hours (max 24 hours). Appendicular stump was treated by electrocautery

in Group A and povidone-iodine in Group B. In Group A monopolar electrocautery set on coagulation mode with 50 W powers was used. The conventional Bovie tip was touched superficially on exposed mucosa for 2-3 seconds till only mucosa got cauterized. In Group B, a swab soaked in 10% w/v povidone-iodine solution was applied over the appendix stump covering its surface with the drug. In both groups, a second culture swab (Sample 2) from treated stump was taken after 5 minutes. The samples were sent to microbiology laboratory. Microbiologist was unaware of the intervention group. The patients were followed up till one month postoperatively. The primary outcome measure was absence of bacterial growth on the cultures obtained after application of either of the treatment (electrocautery/ povidone-iodine), considering it as an effective therapy. Secondary outcome measures included wound infection and hospital stay. Pus or purulent fluid discharge from the wound with pain, inflammation of skin edges within 30 days of operation was considered as wound infection.

Statistical Analysis

SPSS (version 20) was used for data entry and analysis. Qualitative variables were presented as percentages and quantitative variables were presented as mean±SD. Difference in age and hospital stay was determined by student's *t*-test. Comparison in terms of effective therapy and wound infection was done by Pearson Chi-square test. A *p*-value ≤0.05 was considered as statistical significant.

RESULTS

Total 63 patients who underwent appendectomy were analyzed, however only 40 patients were recruited for this study. Rest of the 23 patients was excluded due to absence of culture growth from the specimen taken before the application of either intervention. (Figure 1)

The mean age of the patients was 25.5 ± 9.9 years. Regarding gender distribution, 27 (67%) were males and 13 (33%) were females. In group A, there were 15 (75.0%) males and 5 (25.0%) females with mean age of 26.6 ± 10.02 years. In group B, 12 (60.0%) were males and 8 (40.0%) were females with mean age of 24.5 ± 10.1 years. No statistically significant difference was found in age (*p*=0.51) and gender (*p*=0.31) distribution among both groups.

Appendicular Stump Disinfection Using Povidone- iodine Swab Compared with Electrocautery; which one

Intervention was found to be effective in 20 (100%) patients in group A and in 12 (60%) patients in group B (Figure 2). Statistically significant difference was found between the two groups ($p < 0.05$). However there was no reported iatrogenic injury to gut while using electrocautery.

Overall post-operative superficial wound infection was found in total 7 (12.5%) patients with 3 (15%) cases in group A and 4 (20%) cases in group B. ($p = 0.67$). (Table 1). While assessing the effectiveness of the therapy and wound infection, it was found out that wound infection occurred in 4

out of 32 (12.5%) patients in effective therapy group (20 in group A and 12 in group B) versus 3 out of 8 (37%) patients in ineffective therapy group (8 in group B). Relationship between wound infection and effectiveness of the therapy was statistically insignificant ($p = 0.096$). All patients were managed conservatively by providing pus drainage, daily dressings and with antibiotics.

The mean hospital stay in group A was 1.60 ± 0.68 days while it was 1.25 ± 0.44 days in group B (Table 1).

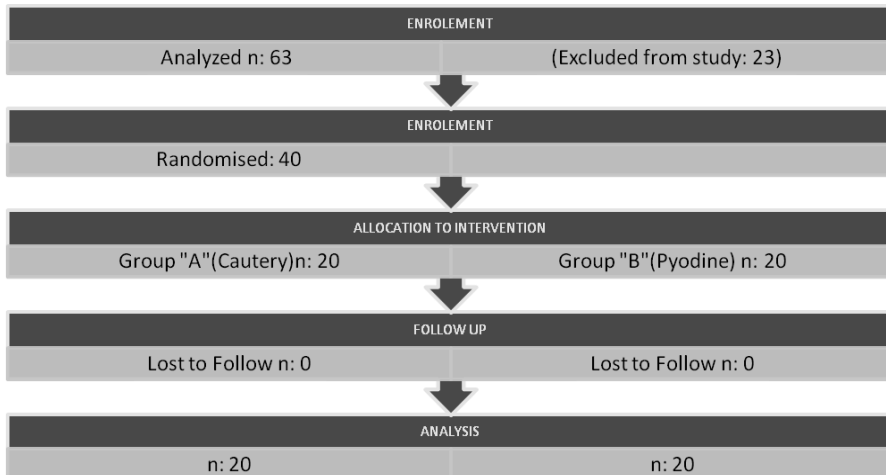


Figure 1: Randomized controlled trial to check the effectiveness of electro-cautery vs. povidone-iodine in appendicular stump disinfection

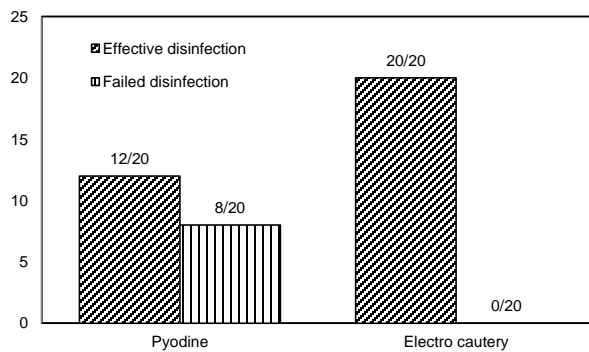


Figure 2: Effectiveness of povidone-iodine and electrocautery in appendix stump disinfection

Table 1: Secondary outcome variables in both study groups

Variables	Group A (Electro-cautery) n=20	Group A (Povidone-iodine) n=20	p-value ¹
Wound Infection			
• Yes	03	04	0.67
• No	17	16	
Hospital Stay (No. of days)	1.60 ± 0.68	1.25 ± 0.44	0.06

¹Chi square test was used to calculate p-value. p-value ≤0.05 was considered as significant.

Table 2: Organisms isolated in culture reports (N=40)

Isolates	Frequency (%)
<i>E. coli</i>	6 (15.0)
<i>Pseudomonas spp.</i>	14 (35.0)
<i>Klebsiella spp.</i>	17 (42.5)
<i>Proteus spp.</i>	3 (7.5)

Table 3: Results of Individual antibiotic sensitivity (N=40)*Some isolates were having sensitivity to more than one antibiotics

Antibiotics	Frequency (%)
Amikacin	34 (85)
Sparfloxacin	23 (57)
Ciprofloxacin	9 (22.5)
Tazobactam	6 (15)
Gentamycin	2 (5)
Amoxicillin/Clavulanic acid	2 (5)

Table 4: Result of Isolates sensitive to two or more antibiotics.(N:40)

Antibiotics	Frequency (%)
Amikacin, Amoxicillin/Clavulanic acid	2(5)
Amikacin , Ciprofloxacin	5 (12.5)
Amikacin , Sparfloxacin	19 (47.5)
Amikacin, Tazobactam	6 (15)
Ciprofloxacin, Sparfloxacin	2 (5)
Sparfloxacin, Gentamycin	2 (5)

DISCUSSION

Most recommended procedure in appendectomy is cauterization of appendicular stump for disinfection to avoid wound infection and adhesion

formation^(9,10,11,12). Povidone-iodine swab application on exposed mucosa is also widely practiced and recommended⁽¹³⁾. The current study tried to find out scientific basis of this practice and the relationship of disinfected stump with post-operative wound infection.

Appendix stump is potentially contaminated as appendix harbors a mixed pattern of microorganisms predominantly anaerobes, especially *Bacteroides fragilis* and aerobes including *E. coli* and *Pseudomonas*. There was no qualitative difference in bacterial flora of normal or acutely inflamed appendix although tissue ischemia favors anaerobic and microaerophilic organisms⁽¹⁴⁾. The aerobic isolates from appendix stump mostly showed *Klebsiella spp.* in 17 (42.5%), *Pseudomonas spp.* in 14 (35%) and less commonly *E. coli* in 6 (15%) patients. This finding was different from earlier reports in which *E coli* was the most commonly isolated organism and pseudomonas was second common aerobic microorganism with a noted predominance of anaerobes⁽¹⁴⁾ (Table 2). In current study, most effective antibiotic was Amikacin with susceptibility of 34 (85%) samples and second to it was Sparfloxacin, effective against 23 (57%) samples (Table 3). Similarly if we evaluate bacterial isolate sensitivity to two or more antibiotics, Amikacin and Sparfloxacin was on the top of list with 19/40 (47.5%) isolates.(Table 4)

Although Povidone-iodine is frequently applied on appendicular stump but in review of literature, no definitive guidelines favoring its use on appendix stump could be retrieved. Povidone-iodine being a powerful disinfectant is routinely used in preoperative skin preparation. 10% w/v solution is usually used and it has shown widespread antimicrobial activity covering bacteria, fungi and viruses as documented by Bogash (1956)⁽¹⁵⁾. In spite of its widespread antibacterial activity, the results of the current trial dictate that Povidone-iodine was effective in only 12 (60%) cases, as compared to electrocautery 20 (100%) cases (Figure 2). Possible explanations of its decreased effectiveness could be attributed to possibly decreased contact time and diluted Povidone-iodine solution. Another important factor could be very little or nil fluid present on stump for 2nd sample as the fluid could have already been absorbed by 1st sample swab. One study done in India, in vitro showed that povidone-iodine may need a contact time of 15 minutes for its bactericidal effect⁽¹⁶⁾.

Commented [FAR1]:
NOUMAN SB

This table needs re-alignment. I think it should be at the bottom spanning both columns (full page width).

Appendicular Stump Disinfection Using Povidone- iodine Swab Compared with Electrocautery; which one

Current literature favors using electrocautery; theoretically it exerts its effects at the same time^(10,11). Heat exerts bactericidal action at some distance from point of application of electric probe whereas acid acts only on the surface⁽¹⁷⁾. Cauterization ablates the mucosa and seals the stump and is believed to minimize the theoretical risk of mucocele formation^(3,10). Extreme care must be taken to avoid accidental bowel injury, particularly using monopolar current. This can lead to subsequent necrosis, sloughing and ceecal fistula formation⁽⁹⁾.

According to literature, overall wound infection rate after uncomplicated appendectomy is 10-20%⁽¹⁸⁾. Our study showed wound infection rate of 17%, which is comparable to previous studies. While assessing possible relationship between wound infection and effective appendix stump disinfection. Out of 32 (20+12), cases who were effectively treated, as shown by negative culture reports after application of either intervention (cautery/ povidone-iodine), 4 (12%) cases developed wound infection. Though, this percentage was lower as compared to 'In effectively treated' group, where 3 out of 8 (37%) patients develop wound infection, again it is statistically insignificant ($p = 0.096$). There was no patient in the follow-up period with suspicious intra abdominal adhesions. In the literature 70% of cases of post-operative wound infection, the bacteria isolated from wound infection were same as isolated from appendix swab⁽¹⁹⁾ However, in another research positive cultures during appendectomy did not predict the development of postoperative abscess or influence its treatment⁽¹⁶⁾. In present study, infected wound culture swabs could not be isolated to compare them with appendix stump isolates.

Intra-operative culture during appendectomy had been a routine practice but with poor yield. Literature reports wide variation in positive culture, ranging from 18-95%⁽⁴⁾ We also had 23 out of 63 (36%) rate of negative culture report of swabs taken from appendicular stump before applying any intervention and these cases were excluded from the study (Figure 1).

Current study showed electrocautery is better than Povidone-iodine in disinfecting appendicular stump. Small sample size, non-availability of anaerobic culture facilities, decreased contact time and strength of Povidone-iodine may be considered as limitation factors in this study. Further studies are required addressing these

limitation factors to assess type and degree of stump contamination, effective disinfection and its relationship with wound infection.

CONCLUSION

The mucosa exposed after cutting appendix is potentially contaminated. Electrocautery is safe and more effective in disinfecting the appendix stump than with povidone-iodine.

ACKNOWLEDGEMENTS

We are thankful to Dr Muhammad Kamran Saeed, specialist surgeon, Kingdom of Saudi Arabia for help in conception of study.

REFERENCES

1. Ohle R, O'Reilly F, O'Brien KK, Fahey T, Dimitrov BD. The Alvarado score for predicting acute appendicitis: a systematic review. *BMC Med* 2011;9(1): 139-142
2. Rafiq MS, Khan MM, Khan A, Jan H. Receiver operator characteristic curve analysis of the lintula scor for reduction of negative appendectomies in adults. *J Coll Physicians Surg Pak* 2015;25(2): 100-103.
3. Harbin RM. The stump of the appendix, an agent of infection. *Ann Surg* 1934; 99(4): 633.
4. ladman MA, Knowles CH, Gladman LJ, Payne JG. Intra-operative culture in appendicitis: traditional practice challenged. *Ann R Coll Surg Engl* 2004; 86(3): 196.
5. Suvera MS, Kharadi AH, Ansari US, Damor PB, Shah MT, Patel MB. Open appendectomy stump: invaginate or not to invaginate? *Int J Res Med Sci.* 2013; 1(3): 248-251.
6. Rosenberg I. The effect of diathermy to the appendix stump in the control of wound sepsis. *J R Coll Surg Edinb* 1974; 19(6): 381-383.
7. Willis M. The treatment of the appendix stump after appendectomy. *Ann Surg* 1908; 48(1): 74-79.
8. Kochar S. Common surgical emergencies. Delhi, India: JAYPEE Brothers Medical Publisher Limited; 2000.p. 330.
9. Bailey RW, Zucker KA. Atlas of general surgery: laparoscopic assisted appendectomy. 3rd Ed. New Delhi: Jaypee; 2008.p. 610.

10. Smink DS, Soybel DI. Maingot's abdominal operations: appendix and appendectomy: 11th ed. New York: The McGraw-Hill; 2007.p. 589–611.
11. Jaffe BM, Berger DH. Schwartz's principles of surgery. Appendix: 8th Ed. New York: The McGraw hill; 2005. P 1131.
12. Joseph F E, Kirby B I , Mark C P. Mastery of Surgery: Appendicitis and appendiceal abscess. 5th ed. Boston: Wolters and Kluwer, LWW Ltd.; 2007, P1430.
13. Mihaly Boros. Surgical techniques, Textbook for medical students: Basic surgical procedures on the intestine, appendectomy. Szeged: Dr Mihlay Boros; 2006. p.100.
14. Roberts JP. Quantitative bacterial flora of acute appendicitis. Arch Dis Child 1988; 63: 536-540.
15. Gilmore OJA, Martin TDM. Etiology and prevention of wound infection in appendectomy. Br J Surg 1947; 61: 281-287
16. Bapat R D, Supe A N, Sathe M J. Management of small bowel perforation with intra- and post-operative lavages with povidone iodine. (A prospective study). J Postgrad Med 1983;29:29-33.
17. Seelig M. G. The treatment of the stump in appendectomy: based on pathologic and bacteriologic study of the appendix. Ann Surg 1904 Nov; 40(5): 710–720.
18. Bickel A, Gurevits M, Vamos R, Ivry S, Eitan A. Perioperative hyperoxygenation and wound site infection following surgery for acute appendicitis: A randomized prospective controlled trial. Arch Surg 2011;146(4):464-470.
19. Gottrup F, Hunt TK. Antimicrobial prophylaxis in appendectomy patients. World J Surg 1982; 6: 306-311.