

Histoacryl® (N-butyl-2-cyanoacrylate) injection mixed with olive oil for endoscopic treatment of gastric varices – an equally safe alternative

Muhammad Bilal Nasir¹, Junaid Mushtaq², Ibtessam Amjad³, Ghias un Nabi Tayyab⁴, Israr ul Haq⁵, Shafqat Rasool¹, Ghias ul Hassan¹

¹Assistant Professor, ²Medical Officer, ³Post Graduate Resident, ⁴Professor, ⁵Associate Professor, Division of Gastroenterology & Hepatology Medical Unit 1, Post Graduate Medical Institute/LGH, Lahore.

Correspondence to: Medical Unit 1, Lahore General Hospital, Ferozepur Road, Lahore. Email: drbilalnasir@hotmail.com

ABSTRACT

Background: Ethiodized oil (Lipiodol®) is a commonly used but an expensive oil-based carrier to facilitate injection Histoacryl® (N-butyl-2-Cyanoacrylate) to treat gastric varices. This study evaluates the efficiency and safety of olive oil as a cheaper oil-based carrier for injecting Histoacryl® (N-butyl-2-Cyanoacrylate) to obliterate gastric varices endoscopically.

Subject and Methods: This prospective observational study was carried out at Gastroenterology Department, Lahore General Hospital, Lahore from January 2014 to December 2016. Total of 132 patients of gastric varices diagnosed on upper gastrointestinal endoscopy and obliterated using Histoacryl® injections mixed with olive oil were enrolled. Sarin's classification was used to classify the gastro-oesophageal varices (GOV) into four types. Successful hemostasis was defined as hemodynamic stability, no rebleeding episode and no further drop in hemoglobin within 24 hours following sclerotherapy.

Results: According to Sarin classification, 69 (52.3%), 56 (42.4%) and 7 (5.3%) patients had GOV2, GOV1 and isolated gastric varices respectively. Mean age was 57.3 year and 87 (65.9%) patients were male. Large bulging varices with visible platelet plug were present in 84% patients. Out of 132 patients, 92 (69.69%), 34 (25.75%) and 6 (0.04%) patients received 1, 2 and 3 sessions respectively. Successful hemostasis after first injection was achieved in 128 (97%) cases. Twenty five (18.9%) patients presented with re-bleeding in six months and the rate of re-bleed was higher in GOV2. No immediate or long-lasting complications for Histoacryl® (N-butyl-2-cyanoacrylate) injection mixed with olive oil occurred in these cases during follow-up.

Conclusion: Histoacryl® injection with olive oil based carrier is an equally effective, rapid, easy, cheap and alternative for routine clinical use in endoscopic treatment of gastric varices.

Keywords:

Gastric varices, Histoacryl®, Olive oil, Lipoidal, Effectiveness

INTRODUCTION

The association of gastric varices were initially reported in 1913.¹ Variceal hemorrhage is one of the major causes of mortality and morbidity in patients of liver cirrhosis with significant portal hypertension.² Whereas esophageal varices are common source of bleeding in these patients, gastric varices can be present in 5-33% of patients.³ Bleeding gastric varices have a more severe and higher re-bleeding and mortality rate than esophageal varices.⁴ Gastro-oesophageal varices (GOV) have been categorized as GOV-1 (Esophageal varix extending down to cardia or lesser curve) and GOV-2

(esophageal & fundal varices). Isolated gastric varices if found only in the fundus of stomach is isolated gastric varices-1 and anywhere else in the stomach other than fundus is isolated gastric varices-2.⁵ Risk factors for bleeding of gastric varices reported on endoscopy are; site inside the fundus, Child's-Pugh class, existence of red spot and the size of varices.⁶ Endoscopic Variceal Band Ligation (EVBL) is most commonly employed for initial treatment of esophageal variceal bleeding but is not as successful for bleeding gastric varices. Alternative treatments for gastric varices bleeding are; endoscopic injection of sclerosing agents "Thombin or N-Butyl-Cyanoacrylate glue" (Histoacryl®), Trans-jugular Intrahepatic Porto-Systemic Shunt placement (TIPSS), or Balloon Occluded Retrograde Transvenous Obliteration.⁷ Since 1984, N-Butyl-2-Cyanoacrylate (Histoacryl®) injection has been reported to be effective

Competing interest: The authors have declared no competing interests exist.
Citation: Nasir MB, Mushtaq J, Amjad I, Tayyab GN, Haq I, Rasool S, Hassan G. Histoacryl® (N-butyl-2-cyanoacrylate) injection mixed with olive oil for endoscopic treatment of gastric varices – an equally safe alternative. J Fatima Jinnah Med Univ 2018; 12(3): 102-105.

treatment for gastric varices bleeding with initial hemostasis in 70-95% cases in acute gastric varices bleeding and re-bleeding rate of 0-28% in the first 48h.⁸⁻¹⁰ N-Butyl-2-Cyanoacrylate (NBC) polymerizes into a plastic cast from liquid glue when came into contact with blood in varix and achieves control of active bleeding. Recent meta-analysis on complications (end-organ infarction, systemic embolization, bacteremia and visceral fistula) of patients treated with Histoacryl® reported it to be comparatively safe, harmless and effective.¹¹⁻¹² Its use with an oil-based carrier, like Lipiodol®, is recommended as first-line treatment option for gastric varices.¹⁰⁻¹² However Lipiodol® is an expensive product and increases the total cost of treatment. This study attempts to find out the safety and effectiveness of a cheaper alternative oil based carrier (olive oil) with NBC injection to obliterate gastric varices endoscopically.

PATIENTS AND METHODS

This prospective observational study was carried out at the Gastroenterology Department of Lahore General Hospital, Lahore from January 2014 till December 2016. Total of 132 patients diagnosed to have gastric varices on upper GI endoscopy, incidental or bleeding, were evaluated for successful hemostasis and complications. Patients with history of previous sclerotherapy, chronic renal failure, diabetes mellitus, chronic obstructive pulmonary disease, malignancy and those with massive bleeding impairing endoscopic vision were excluded. All patients underwent complete clinical review and baseline laboratory studies including, complete blood count, liver function tests, basic metabolic panel, and coagulation profile. Patients presenting with active bleeding varices had blood grouping and cross matching and blood products were arranged. Vasoactive drug, somatostatin analogue, was started before endoscopy. All patients received a prophylactic antibiotic dose of 1 gram intravenous Cefotaxime. Varices were classified as proposed by Sarin and associates; GOV-1: varices along lesser curve, GOV-2: varices along fundus of stomach and isolated gastric varices.⁴ Injection was made in the varices using 1ml of Histoacryl® dissolved in 0.5ml of olive oil followed by a push of 1.5ml olive oil through a 19-Gauge Olympus injector needle. Obliteration was confirmed by using the tip of the uncovered injector and direct endoscopic visualization of the varix. Post-procedure all patients were shifted to intensive care unit for strict observation; monitoring of vital signs and signs of re-bleeding. Successful hemostasis was defined

as hemodynamic stability, no rebleeding episode and no further drop in hemoglobin within 24 hours following sclerotherapy. Rebleeding was defined as evidence of hematemesis and/or melena, hemodynamic instability (drop of > 20 mm Hg in systolic pressure from baseline), drop in hemoglobin of 2 mg/dL or a transfusion requirement of ≥ 2 units of packed red blood cells after 24 hours. If a patient showed evidence of re-bleeding, a repeat endoscopy with NBC was performed. All patients were followed up in out patient clinics for 1 year post-procedure and any complications were documented in the chart. Data was entered in SPSS version 20. Quantitative variables like age was expressed as mean \pm SD. Frequency with percentages were calculated for qualitative variables; gender, etiology, type of varices, findings on endoscopy, number of endoscopies per patient, efficacy, rate of re-bleeding and the associated complications.

RESULTS

Total of 132 patients with endoscopically identified gastric varices were enrolled. Eighty seven (65.9%) were male and 45 (34.1) females with male to female ratio of 1.9:1 (male predominance). Mean age was 57.3 (± 2.34) years; range 44 to 65 years. Distribution of gastric varices is depicted in Figure 1. Endoscopic findings showed small varices in 21(15.9%) and large varices in 111(84.1%) patients. Total of 107 patients (81.1%) had endoscopy due to hematemesis while another 25 (18.9%) were identified during surveillance endoscopy done due to underlying liver disease. Hepatitis C was the most common etiology, found in 88 patients (66.7%). One (0.8%) patient had Hepatitis B while 43/132 (32.5%) patients had various other causes including non-alcoholic liver disease, alcoholic liver

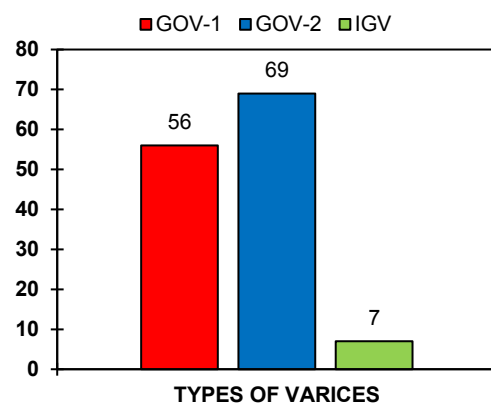


Figure 1. Distribution for gastric varices

disease, Budd-chiari syndrome, etc. Initial hemostasis was achieved in 128 (97%) patients. Re-bleeding was noted in 25 patients (18.9%). All patients with re-bleeding had repeat endoscopy. Patients identified and injected during surveillance endoscopy did not have bleeding pre or post endoscopy. Among 25 patients with re-bleeding, 20 (80%) had previously documented GOV-2 on endoscopy. Successful endoscopic control of re-bleeding was achieved in 22 (88%) patients while 3 (12%) patients needed surgical intervention. Number of endoscopic sessions required for bleeding control is shown in Figure 2. All participants of the study were followed for 1 year (post-treatment) in the GI clinic. There were no immediate or late serious or adverse events recorded with N-Butyl-2-Cyanoacrylate (Histoacryl®) with olive oil injection.

DISCUSSION

Bleeding from gastric varices is the most serious life-threatening condition in patients with portal hypertension. Emergency management includes volume resuscitation and octeriotide or terlipressin therapy.^{13,14} An emergent endoscopy is required in patients suspected of active variceal bleed to verify the diagnosis and perform a targeted therapy.¹³ Therapeutic options may be endoscopic (sclerosing agents) or non-endoscopic (radiological or surgical). Histoacryl® with Lipiodol® injection has demonstrated initial hemostasis rates ranging from 88-100%.¹⁵⁻²² With Histoacryl® and olive oil based injection, an endoscopic hemostasis was achieved in 97% cases in this study. The rate of gastric variceal re-bleeding observed is 18.9%. This re-bleeding rate is well within previously reported 17 to 59% reported in the literature.^{18,19} Compared to esophageal varices, endoscopic management of gastric varices bleeding is not well-developed. Non Endoscopic Methods, such as TIPSS and surgical portosystemic shunt creation, although well established and effective, are technically difficult, more invasive and have complication rates of 10% to 30%.¹⁹ The treatment methods of esophageal varices are also applied for gastric varices including i.e. band ligation and injection of sclerosing agents, but limited success for hemostasis was achieved in gastric varices bleeding.²⁰⁻²³ Re-bleeding rates of 0 to 28% have been reported in the literature within the first 48 hours of the procedure.¹⁹ In one study, re-bleeding was 23.3% observed within 3 days to 16 months.²⁴ In this study, the efficacy of Histoacryl® in terms of initial hemostasis is 98.4% which was reported better than this in other studies.²⁵ The reported re-

■ One session ■ Two Sessions ■ Three Sessions

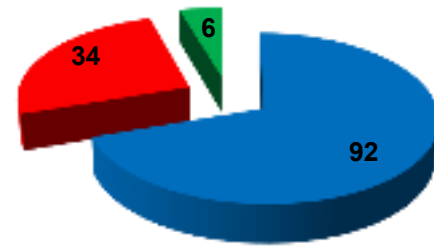


Figure 2: Endoscopic sessions for achieving hemostasis

bleeding ranged from 22-59% with Histoacryl® injection for management of acute gastric variceal bleeding.²⁶ Rebleeding was more common in GOV-2 in this study, which is similar to other reports.¹⁹ No significant complications of cyanoacrylate injection with olive oil were observed in this study. Although rare but serious adverse reaction of glue injection have been widely reported including cases of fatal pulmonary embolism.²⁷ Hwang and coworkers described the complications of glue injection in 5.2 % of the patients; including 3.1% early re-bleeding and 0.3% embolic complications like stroke, deep vein thrombosis, coronary embolism, splenic infarction and non-fatal pulmonary embolism in.²⁸ Kang and group reported infective complications in 34% and abdominal pain in 17% patients in their study of 127 patients.¹⁹ No significant complication was observed in this study. There are only few randomized, prospective studies comparing the use of glue with traditional endoscopic methods for managing bleeding gastric varices. Two studies compared glue injection with gastric variceal band ligation in patients with acute bleeding.²⁹ Lo and group observed use of glue to be more effective in achieving immediate hemostasis (87% versus 45%; $P=0.03$) and in preventing rebleeding (69% versus 46%; $P=0.005$).²⁰ Tan and coworkers reported no difference in controlling active bleeding in the two groups but a significantly less re-bleeding in cases received glue (22% versus 44%; $P < 0.05$).²⁸

CONCLUSION

Histoacryl® injection with olive oil based carrier for endoscopic treatment of gastric varices is an equally effective and cheaper alternative than with Lipiodol® based treatment.

REFERENCES

- Lunderquist A, Börjesson B, Owman T, Bengmark S. Isobutyl 2-cyanoacrylate (bucriylate) in obliteration of gastric coronary vein and esophageal varices. *AJR Am J Roentgenol.* 1978; 130: 1-6
- De Franchis R. Portal hypertension IV - Proceedings from the 4th Baveno International Consensus Workshop. *J Hepatol.* 2005; 42:147-8.
- Feu F, Garcia-Pagan JC, Bosch J, Luca A, Teres J, Escorsell A, et al. Relation between portal pressure response to pharmacotherapy and risk of recurrent variceal haemorrhage in patients with cirrhosis. *Lancet.* 1995; 346(8982):1056-9.
- Sarin SK, Lahoti D, Saxena SP, Murthy NS, Makwana UK. Prevalence, classification and natural history of gastric varices: a long-term follow-up study in 568 portal hypertension patients. *Hepatology.* 1992; 16(6):1343-9.
- Sarin SK, Kumar A. Gastric varices: profile, classification, and management. *Am J Gastroenterol.* 1989; 84(10): 1244-9.
- Hashizume M, Kitano S, Yamaga H, Koyanagi N, Sugimachi K. Endoscopic classification of gastric varices. *Gastrointest Endosc.* 1990; 36(3): 276-80.
- Kanagawa H, Mima S, Kouyama H, Gotoh K, Uchida T, Okuda K. Treatment of gastric fundal varices by balloon-occluded retrograde transvenous obliteration. *J Gastroenterol Hepatol.* 1996; 11(1): 51-8.
- Rajoriya N, Forrest EH, Gray J, Stuart RC, Carter RC, McKay CJ, et al. Long-term follow-up of endoscopic Histoacryl glue injection for the management of gastric variceal bleeding. *QJM.* 2011; 104(1): 41-7.
- Kojima K, Imazu H, Matsumura M, Honda Y, Umemoto N, Moriyasu H, et al. Sclerotherapy for gastric fundal variceal bleeding: is complete obliteration possible without cyanoacrylate? *J Gastroenterol Hepatol.* 2005; 20(11): 1701-6.
- Fry LC, Neumann H, Olano C, Malfertheiner P, Monkemuller K. Efficacy, complications and clinical outcomes of endoscopic sclerotherapy with N-butyl-2-cyanoacrylate for bleeding gastric varices. *Dig Dis.* 2008; 26(4): 300-3.
- Taghavi SA, Eshraghian A, Hamidpour L, Moshfe MJ. Endoscopic cyanoacrylate injection for the treatment of bleeding gastric varices: the first Iranian series. *Arch Iran Med.* 2012; 15(3): 157-61.
- Linhares MM, Matone J, Matos D, Sakamoto FI, Caetano EM, Sato NY, et al. Endoscopic treatment of bleeding gastric varices using large amount of N-butyl-2-cyanoacrylate under fluoroscopic guidance. *Surg Laparosc Endosc Percutan Tech.* 2008; 18(5): 441-4
- SIGN. Management of acute upper and lower GI bleeding. SIGN Guideline No. 105, ISBN 978 1 905813 37 7, September 2008.
- Soares-Weiser K, Brezis M, Tur-Kaspa R, Leibovici L. Antibiotic prophylaxis for cirrhotic patients with gastrointestinal bleeding. *Cochrane Database Syst Rev.* 2002; (2): CD002907.
- Huang YH, Yeh HZ, Chen GH, Chang CS, Wu CY, Poon SK, et al. Endoscopic treatment of bleeding gastric varices by N-butyl-2-cyanoacrylate (Histoacryl®) injection: long term efficacy and safety. *Gastrointest Endosc.* 2000; 52(2):160-7.
- Iwase H, Maeda O, Shimada M, Tsuzuki T, Peek RM Jr, Nishio Y, et al. Endoscopic ablation with cyanoacrylate glue for isolated gastric variceal bleeding. *Gastrointest Endosc.* 2001; 53(6): 585-92.
- Seewald S, Naga M, Onar S, Okasha S, Imazu H, Groth S, et al. Standardised injection technique and regimen minimises complication and ensures safety of N-Butyl- 2-Cyanoacrylate injection for the treatment of Gastric Fundal Varices. *GastroIntest Endosc.* 2005; 61(5): AB91.
- Seewald S, Ang TL, Imazu H, Naga M, Omar S, Groth S, et al. A standardized technique and regimen ensures success and safety of N-butyl-2-cyanoacrylate injection for the treatment of gastric fundal varices. *Gastrointest Endosc.* 2008; 68(3): 447-54.
- Kang EJ, Jeong SW, Jang JY, Cho JY, Lee SH, Kim HG, et al. Long-term result of endoscopic Histoacryl® (N-butyl-2-cyanoacrylate) injection for treatment of gastric varices. *World J Gastroenterol.* 2011; 17(11): 1494-1500.
- Helmy A, Hayes PC. Review article: Current endoscopic therapeutic options in the management of variceal bleeding. *Aliment Pharmacol Ther.* 2001; 15(5): 575-94.
- Lo GH, Lai KH, Cheng JS, Chen MH, Chiang HT. A prospective, randomized trial of butyl cyanoacrylate injection versus band ligation in the management of bleeding gastric varices. *Hepatology.* 2001; 33(5):1060-4.
- Maluf-Filho F, Sakai P, Ishioka S, Matuguma SE. Endoscopic sclerosis versus cyanoacrylate endoscopic injection for the first episode of variceal bleeding: a prospective, controlled, and randomized study in Child-Pugh class C patients. *Endoscopy.* 2001; 33(5): 421-7.
- Kind R, Guglielmi A, Rodella L, Lombardo F, Catalano F, Ruzzenente A, et al. Bucriylate treatment of bleeding gastric varices: 12 years' experience. *Endoscopy.* 2000; 32(7): 512-19.
- Akahoshi T, Hashizume M, Shimabukuro R, Tanoue K, Tomikawa M, Okita K, et al. Long-term results of endoscopic Histoacryl® injection sclerotherapy for gastric variceal bleeding: a 10-year experience. *Surgery.* 2002; 131(1 Suppl): S176-81.
- Paik CN, Kim SW, Lee IS, Park JM, Cho YK, Choi MG, et al. The therapeutic effect of cyanoacrylate on gastric variceal bleeding and factors related to clinical outcomes. *J Clin Gastroenterol.* 2008; 42(8): 916-22.
- Lo GH, Liang HL, Chen WC, Chen MH, Lai KH, Hsu PI, et al. A prospective, randomized controlled trial of transjugular intrahepatic portosystemic shunt versus cyanoacrylate injection in the prevention of gastric variceal rebleeding. *Endoscopy.* 2007; 39(8): 679-85.
- Saracco G, Giordanino C, Roberto N, Ezio D, Luca T, Caronna S, et al. Fatal multiple systemic embolisms after injection of cyanoacrylate in bleeding gastric varices of a patient who was noncirrhotic but with idiopathic portal hypertension. *Gastrointest Endosc.* 2007; 65(2): 345-7.
- Hwang SS, Kim HH, Park SH, Kim SE, Jung JI, Ahn BY, et al. N-butyl-2-cyanoacrylate pulmonary embolism after endoscopic injection sclerotherapy for gastric variceal bleeding. *J Comput Assist Tomogr.* 2001; 25(1): 16-22
- Tan PC, Hou MC, Lin HC, Liu TT, Lee FY, Chang FY, et al. A randomized trial of endoscopic treatment of acute gastric variceal hemorrhage: N-butyl-2-cyanoacrylate injection versus band ligation. *Hepatology.* 2006; 43(4): 690-7.