

---

ORIGINAL ARTICLE

# Histological Pattern of Ovarian Tumors in Women Presenting in a Tertiary Care Hospital

MUNAZZA IQBAL<sup>1</sup>, FARIA FASIH<sup>2</sup>, FARRUKH KAMAL<sup>3</sup>

<sup>1</sup>Associate Professor of Pathology, Fatima Jinnah Medical College / Sir Ganga Ram Hospital, Lahore. <sup>2</sup>Demonstrator, Department of Pathology, Fatima Jinnah Medical College / Sir Ganga Ram Hospital, Lahore. <sup>3</sup>Professor Pathology Department, Fatima Jinnah Medical College / Sir Ganga Ram Hospital, Lahore

Correspondence Author: Dr. Munazza Iqbal, M.B.B.S, M.PHIL, Associate Professor of Pathology, Fatima Jinnah Medical College, Sir Ganga Ram Hospital, Lahore. Email: khalidmasoodgondal@yahoo.com

## ABSTRACT

**Background:** The risk of having ovarian tumor in female at sometime in her life is 6-7%. Relative frequency of ovarian tumor is different for Western and Asian countries. Identification of various histological patterns is important for correct diagnosis, which further affects treatment and prognosis.

**Objective:** To evaluate the frequency of histological patterns of ovarian tumors in women presenting in a tertiary care hospital.

**Methodology:** This descriptive cross-sectional study included 100 cases of ovarian tumors reported in department of pathology, Fatima Jinnah Medical College/Sir Ganga Ram Hospital, Lahore. SPSS version 20 was used for analysis of data.

**Results:** Out of 100 ovarian tumors included, 52% were benign and 48% were malignant. Mean age was 35 years ranging from 10 to 70 years. Surface epithelial tumors were most common (62%) followed by germ cell tumors 32%. Most frequently occurring benign tumor was serous cystadenoma (20%) while malignant tumor was serous cystadenocarcinoma (25%).

**Conclusion:** Benign tumors outnumbered malignant tumors but this difference was not very large. Surface epithelial tumors were most common type. Serous cystadenoma was most common benign tumor and serous cystadenocarcinoma was most common malignancy.

**Key words:** Ovarian tumor, Surface epithelial tumor, Adenocarcinoma.

## INTRODUCTION

Ovarian tumors are a common form of neoplasia in women and one of the major health problems. It accounts for 15-25% of all gynecological malignancies.<sup>1</sup> ovarian cancer is the 6<sup>th</sup> most common cancer in females in United States of America.<sup>2</sup>

There are numerous types of ovarian tumors, both benign and malignant. Histogenesis of ovarian tumor includes a complex wide spectrum of neoplasm depending upon the origin of the cell.<sup>2</sup> Risk factors are considered to be nulliparity and family history.<sup>3</sup>

Ovarian tumors array from benign cysts to highly aggressive malignant tumors.<sup>4,5</sup> Benign ovarian cysts may occur at any point in the life but they are most common during child bearing age and constitute about 90% of ovarian tumors. Most benign tumors are cystic and findings of solid elements make malignancy more likely.<sup>6,7</sup>

The recognition of the various histological patterns is important for correct diagnosis, which

has important implications for treatment and prognosis.<sup>1</sup>

The present study was undertaken to find the frequency of different histological types of ovarian tumors in our local population. Many local studies have been conducted on histological patterns of ovarian tumors but they all showed variable results. So keeping in view that the frequency of types of ovarian tumors varies in different geographical regions and has variable results in local literature; this study is being conducted to regenerate local magnitudes.

## MATERIALS & METHODS

This descriptive cross-sectional study was conducted in the department of Pathology, Fatima Jinnah Medical College from 08-12-2010 to 08-09-2011. Specimens of ovarian tumors sent for the histopathological examination were included in the study. Cases with endometriosis and patients with two different synchronous ovarian tumors were excluded. The tumors were classified according to

World Health Organization classification of ovarian tumors. SPSS version 20 was used to analyze the data.

## RESULTS

There were total 100 women who were enrolled in this study. Out of total, 52(52%) were found to be benign and 48(48%) malignant. Age range of women was 10-70 years with mean age of 35 years.

**Table I:** Types of Ovarian Tumors N=100

Type of tumour	Number of Individuals	Percentage
Surface epithelial tumor	62	62%
Germ cell tumor	32	32%
Sex cord tumor	5	5%
Metastatic tumor	1	1%

**Table II:** Surface Epithelial Tumors N=62

Surface epithelial tumour	Number of patients	Percentage
Serous tumours	29	72.5%
Mucinous tumours	11	27.5%

**Table III:** Pattern of Tumors N=100

Type of tumour	Number of patients	Percentage
Serous cyst adenoma	20	20%
Serous cyst adenocarcinoma	25	25%
Mucinous cyst adenoma	9	9%
Borderline mucinous tumour	2	2%
Mucinous cyst adenocarcinoma	6	6%
Teratoma	22	22%
Dysgerminoma	3	3%
Carcinoid tumour	1	1%
Struma ovarii	3	3%
Papillary carcinoma in struma ovarii	1	1%
Sclerosing stromal tumour	2	2%
Granulosa cell tumour	3	3%
Yolk sac tumour	1	1%
Metastatic tumour	2	2%

Out of total 100 patients, 62 patients had surface epithelial tumor, 32 had germ cell tumor, 5 had sex cord tumor and 1 patient had metastatic tumor (table I).

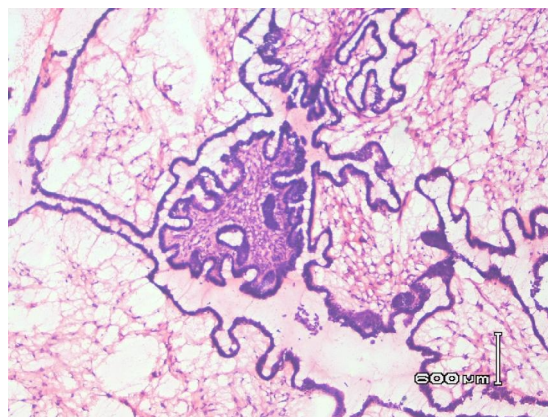
Out of 62 patients having surface epithelial tumor, 45 had serous tumors and 17 had mucinous tumors (table II).

In 45 patients who had serous tumors, 20 had benign serous cystadenoma and 25 had serous cystadenocarcinoma (table III).

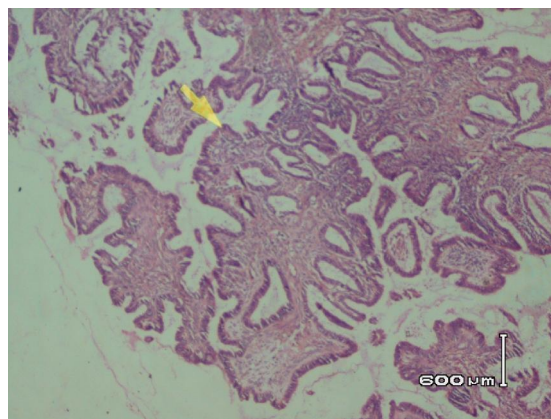
Out of 17 patients having mucinous tumor, 9 patients had mucinous cystadenoma, 2 had borderline mucinous tumor and 6 patients had mucinous cystadenocarcinoma (table III).

Numbers of patients suffering from germ cell tumor were 32, out of which, 22 patients had teratoma, 3 had dysgerminoma, 1 had yolk sac tumor, 1 had carcinoid tumor and 3 patients had struma ovarii (table III).

**Figure 1:** Photomicrograph of Serous Cyst Adenoma



**Figure 2:** Photomicrograph of Serous Cyst Adenocarcinoma



## DISCUSSION

Ovary is a complex structure with different types of cells i.e. germ cells, follicular cells and mesenchymal cells, each having variable potential to form tumors.<sup>8</sup> This constitutes a wide range of neoplastic entities with diverse morphological and clinical manifestations.<sup>1</sup>

Age range of subjects in the study was 10 to 70 years with a mean age of 35 years. Most commonly affected age group was 31-40 years. It was somewhat different from studies done by Maqwana H<sup>8</sup> and Ashraf A<sup>9</sup> who quoted this range as 21-30 years while Suhail I<sup>10</sup> found it to be >40 years. This difference may be due to some variation in the inclusion criteria.

In our study, 52% tumors were benign and 48% were malignant that is inline with the local study carried out in Agha Khan University Hospital Karachi<sup>11</sup> But in studies conducted by Jha R<sup>12</sup> and Vaidya S<sup>1</sup>, incidence of benign cases was reported to be higher than malignant i.e in a ratio of 80:20.<sup>5</sup> Similarly, one of the local studies by Suhail I<sup>10</sup> quoted benign tumors in majority i.e. 79%. This shows geographical variation regarding histological spectrum of ovarian tumors.

In-line with previous studies,<sup>1,12</sup> the most common ovarian tumor in this study was surface epithelial tumor, 62 females (62%). This finding is close to results shown by other studies as 64%, 66% and 70%<sup>11,13,14</sup>, while Guppy et al documented a higher incidence of epithelial tumors than in our study i.e. 90%. This difference may be due to sample size but we cannot rule out the role of genetic, socioeconomic and environmental factors.

Germ cell tumors in our study were 32(32%). In favor of our study, Jindal U<sup>3</sup> also quoted 32.07% germ cell tumor whereas Maqwana H<sup>8</sup> reported germ cell tumors to be 22.86, Malli M<sup>2</sup> reported as 14%. However, a Nepali study showed germ cell tumor to be the most common variety 52%<sup>1</sup> and Ashraf A as 43%.<sup>9</sup>

Out of 62 patients having surface epithelial tumor, 45 (72%) had serous tumors and 17( 28%) had mucinous tumors. This finding is reinforced by Maqwana H<sup>8</sup> as 46% and 15% distribution of serous and mucinous tumors. Similarly, local study by Ashraf A<sup>9</sup> quoted these frequencies to be 46% and 33% respectively. However, a Saudi study reported even higher difference i.e. 70% serous and 25% mucinous tumors.

In 45 patients who had serous tumors, 20(44%) had benign serous cystadenoma and

25(55%) had serous cystadenocarcinoma (table III).

Out of 17 patients having mucinous tumor, 9 patients had mucinous cystadenoma, 2 had borderline mucinous tumor and 6 patients had mucinous cystadenocarcinoma (table III). These results make the serous cystadenoma (fig 1) to be most common benign tumor while serous cystadenocarcinoma (fig 2) as most common malignant tumor. Results described by Abdulla LS<sup>15</sup> are in agreement with our finding which, states serous cystadenoma 44.6% and serous cystadenocarcinoma 33.3% to be most common entities. But conflicting data as quoted in another Saudi study showed benign cystic teratoma was the most common benign tumor (35.2%).<sup>16</sup> Similarly, study conducted by Yasmeen S et al shows endometrioid carcinoma to be more prevalent.<sup>17</sup>

Our study also shows that, serous tumors comprise of 72 % of all ovarian tumors, mucinous tumors 27%, teratoma 22%, dysgerminoma 3%, carcinoïd tumor 1%, struma ovarii 3%, sclerosing stromal tumor 2%, yolk sac tumor 1%, and metastatic tumor 2% of all ovarian tumors which were in agreement with the study according to which, serous tumors comprise of 35%-40% of all ovarian tumors, mucinous tumors 12%-15%, teratoma 20%, dysgerminoma 1%, sclerosing stromal tumor 5% and yolk sac tumor 1% of all ovarian tumours<sup>18,19</sup>. These percentages of all ovarian tumors are very close to results of our study. Differences in study period and variation in diagnostic criteria between different pathologist as well as different study designs may explain the differences seen between our study and various study reported worldwide.

## CONCLUSION

Benign tumors outnumbered malignant tumors but this difference was not very large. Surface epithelial tumors were most common type. Serous cyst adenoma was most common benign tumor and serous cystadenocarcinoma was most common malignancy. Germ cell tumors were second most common tumors. However, this study is institution based and has small sample size so results may not be generalized to entire population.

## REFERENCES

1. Vadiya S, Sharma P, KC S, Vidya SA. Spectrum of ovarian tumors in a referral

- hospital in Nepal. *J Pathol Nepal* 2014; 4:539-543
2. Malli M, Viyas B, Gupta S, Desai H. A histological study of ovarian tumors in various age groups. *Int J Med Sci Public Health* 2014;3(3):338-341
  3. Jindal U. Pattern of ovarian neoplasm in rural population, a five year study from tertiary care hospital. *J Evol Med Dent Sci* 2014;3(8): 2033-2039.
  4. Tariq S, Suhail R. Study of ovarian tumors in young girls. *Professional Med J* 2011; 18(1): 41-45
  5. Steward SH, QUERCE TD, Ochman AR, Yrcver BN, Bao R, Bahhj S. Characterization of a carcinogenesis rat model of ovarian pre-neoplasia and neoplasia. *Cancer Res* 2004;64:8177-83
  6. Yasmin S, Yasmin A, Asif M. Clinico-Histological patterns of ovarian tumors in Peshawar region. *J Ayub Med Coll* 2008; 20(4):11-13.
  7. Pioner MS. Prophylactic oophorectomy. Reducing the US death rate from epithelial ovarian cancer, A continuing debate. *Oncologist* 1996; 1:326-30
  8. Makwana H, Maru A, Laqum N, Agni Hotri A, Triwedi N, Joshi J. The relative frequency and histopathological pattern of ovarian masses-11 year study at tertiary care center. *Int Med Sci Public Health* 2014;3(1):81-84.
  9. Ahsraf A, Sheikh A Saeed, Ashfaq A, Akram A, Kamal F, Ahmad N. The relative frequency and histopathological pattern of ovarian masses. *Bio medica* 2012;28:98-102
  10. Sohail I, Hayat Z, Saeed S. A comparative analysis of frequency and patterns of ovarian tumors at tertiary care hospital between two study periods (2010-2012). *JPMI* 2012;26(2):196-200
  11. Ahmad Z, Kiyani N, Hassan SH, Muzzafar H, Gill MS. Histological pattern of ovarian neoplasm. *J Pak Med Assoc* 2000;50(12):416-419.
  12. Jha R, Karki S. Histological pattern of ovarian tumors and their age distribution. *Nepal Med Coll J* 2008; 10(2):81-5.
  13. Gathol ED, Darnal HK. Pattern of ovarian neoplasm in ovarian moleculer. *J Indian Med Assoc* 1990;88:338-339
  14. Tyagi SE, Mahesh Verni V, Tiyagi N et al. Solid tumors of the ovary. *J Indian Med Assoc* 1993;91:227-230
  15. Abdullah LS, Bondagji NS. Histopathological patterns of ovarian neoplasm and their age distribution in the western region of Saudia Arabia. *Saudi Med J* 2012;13(1):61-65.
  16. Mansoor I. Ovarian diseases at King Abdul Aziz University Hospital. *Saudi Med J* 2002;23:1551-1552.
  17. Yasmin S, Yasim A, Asif M. Frequency of bening and malignant ovarian tumors in a tertiary care hospital. *J post Graduate Med Inst* 2006;24:393-397.
  18. Ellenson LH and Pirog EC. The female genital tract. In: Kumar V, Abbas AK, Fausto N, Aster JC. *Pathologic basis of disease.*, Elsevier; 2009. p. 1005-1063
  19. W. Glenn Mccluggage. Morphological subtypes of ovarian carcinoma: a review with emphasis on new developments and pathogenesis. *Pathology* 2011. 43 (5):420-432