

Transabdominal ultrasound as accurate and sensitive modality for diagnosis of ovarian dermoid cyst: a tertiary care hospital experience

Asma Iqbal¹, Shahid Waheed², Basma Khan³, Behram Shahid⁴

¹Senior Registrar, Department of Radiology, Sharif Medical City hospital, Lahore, ²Professor and Head of Radiology Department Sir Ganga Ram Hospital, Lahore, ³Professor and Head of Radiology Department Punjab institute of Cardiology, Lahore, ⁴Observer Department of Radiology Sir Ganga Ram hospital, Lahore.

Correspondence to: Dr Asma Iqbal, E-mail: drasmaiqbal19@gmail.com

ABSTRACT

Background: Transabdominal ultrasound is readily available, cost effective and first line investigation for pelvic pathologies in girls of adolescent age group. It avoids unnecessary radiation exposure due to CT imaging. Ovarian dermoid cyst is common benign pathology among young girls. In present study we have determined the transabdominal ultrasound sensitivity, specificity and diagnostic accuracy for diagnosis of dermoid cyst of ovary taking histopathology as gold standard.

Patients and methods: This cross-sectional study was conducted at Diagnostic Radiology Department, Sir Ganga Ram Hospital Lahore from 25th Nov 2014 to 24th May 2015. In this study 150 patients (age 6 to 25 years) were included with clinical suspicion of ovarian mass or lower abdominal pain. Transabdominal sonography was carried out and diagnosis i.e. presence of ovarian dermoid cyst or its absence were recorded. All the patients (with a lower abdominal/pelvic mass) underwent surgery either by laparoscopy or laparotomy (therapeutic/diagnostic) and postoperative specimen were sent for histopathology. The results of transabdominal sonogram and histopathology were compared taking histopathology as gold standard.

Results: After comparison of results of transabdominal sonography with histopathology the sensitivity, specificity of transabdominal ultrasound were 92.7%, 87.5% and diagnostic accuracy was 91.3%. Negative and positive predictive values were 95.3% and 81.3% respectively.

Conclusion: The transabdominal ultrasound is very accurate and sensitive modality for diagnosis of ovarian dermoid cyst. Moreover transabdominal ultrasound is easily available first line imaging technique for the diagnosis of this common pelvic lesion (dermoid cyst) among adolescent and young girls.

Keywords:

Transabdominal Ultrasound, Ovarian Dermoid Cyst, Mature Ovarian Teratoma

INTRODUCTION

Ovarian dermoid cyst (mature cystic teratoma) is among the most common benign germ cell tumors. They have origin from the germ cell layers (ectoderm, mesoderm and endodermal derivatives).¹ Mature teratoma represents approximately 40% of all ovarian tumors.² It constitutes 73% of ovarian masses in females aged less than 20 years.³ They are slow growing benign lesion and cause pain either due to compression effect when size is increased or torsion. Chemical peritonitis can occur from intraabdominal spill of the fat debris due to rupture. About 47% of patients complain of abdominal pain.⁴ Usual complications are torsion (16%), infection (1%), rupture (upto 4%), autoimmune hemolytic anemia (<1%), malignant transformation (1-2%). For

proper management of complications accurate diagnosis is required.⁵

Ultrasound has become a widely used, very accurate and sensitive modality through which the diagnosis of a dermoid cyst is established.⁶ In literature transabdominal ultrasound have shown high sensitivity, specificity and accuracy.⁷ Failure to diagnose on ultrasound can lead to unnecessary imaging like CT and radiation exposure.⁸ Since dermoid cysts originate from germ cell layer derivatives, they have spectrum of sonographic appearances. They may appear as a purely cystic, solid, or complex mass due to teeth, matted hair and sebum.⁹ Treatment option for ovarian dermoid cysts is mainly surgical, removed by simple cystectomy. Laparoscopy is the preferred method of treatment for dermoid cysts.¹⁰

The rationale of this study was to determine the diagnostic accuracy of transabdominal ultrasound for ovarian dermoid cyst taking histopathology as gold

Competing interest: The authors have declared no competing interests exist.
Citation: Iqbal A, Waheed S, Khan B. Transabdominal ultrasound as accurate and sensitive modality for diagnosis of ovarian dermoid cyst: a tertiary care hospital experience. J Fatima Jinnah Med Univ 2018; 12(4):142-145.

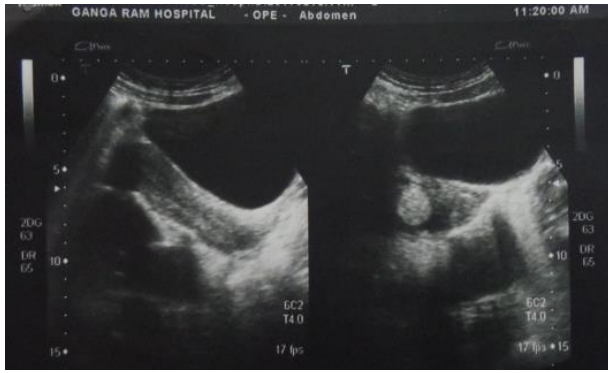


Figure 1. Complex lesion in right ovary predominantly echogenic which was found to be dermoid cyst on histopathology

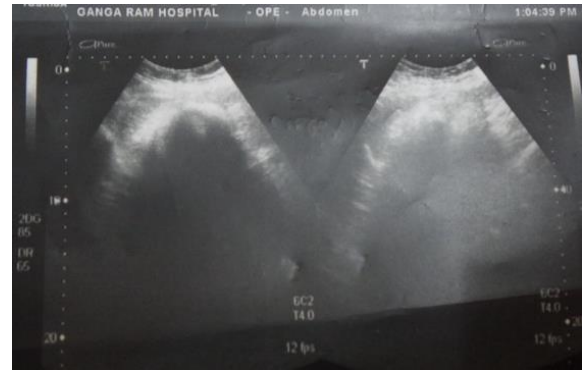


Figure 2. Tip of ice berg sign (intense posterior acoustic shadowing) in dermoid cyst on TAS (confirmed on histopathology)

standard in our population as the international studies have been done upto now show variable results and there was no recent local study available. This study was carried out to show the results in our population. Easy availability and low cost of transabdominal ultrasonography make it preferable to any other radiological investigation. Patients with ovarian dermoid cyst also undergo further investigations like CT scan which gives unnecessary ionizing radiation exposure whereas CT scan and MRI are expensive investigations and not readily available.

PATIENTS AND METHODS

This cross sectional study was carried out at Diagnostic Radiology Department, Sir Ganga Ram Hospital, Lahore with sample of 150 patients, age group 6-25 years, from 25th Nov 2014 to 24th May 2015, after the approval of ethical review committee of Fatima Jinnah Medical University, Lahore. Patients with clinical suspicion of ovarian mass referred by pediatricians/gynecologists from outdoor and emergency departments of Sir Ganga Ram Hospital, Lahore fulfilling the predetermined criteria were enrolled in the study. Inclusion criteria was female patients aged 6-25 years with clinically suspected or pelvic ultrasound lower abdominal mass, ovarian torsion or compression effects. Patients with already diagnosed ovarian mass, not willing to undergo laparoscopy or laparotomy or to be part of study were excluded. Informed consent was obtained. The demographic features i.e. age, and address were recorded. Transabdominal sonogram using 3.5 MHz frequency convex array transducer were carried out on Toshiba (nemio) ultrasound machine. Ultrasonography was done in supine position and using full urinary bladder as imaging window in abdominopelvic scan for females. The uterine cavity, cervix and both ovaries and

posterior cul de sac were clearly visualized. Transabdominal sonogram diagnosis i.e. presence of ovarian dermoid cyst or its absence (i.e. any other ovarian tumor diagnosis) was recorded. On ultrasound patients were diagnosed to have dermoid cyst due to the presence of two or more typical features i.e. heterogeneous cystic lesion with: Fat-fluid level (echogenic fat layer at top and fluid in dependent part of lesion), intracystic mural nodule (Rokitansky nodule), tip of iceberg sign (fatty component at top of cyst obscuring details of cyst), or free floating spherical balls (echogenic). Patients were underwent surgery either by laparoscopy or laparotomy (diagnostic/therapeutic) and postoperative specimen was sent for histopathology. The results of transabdominal sonogram and histopathology were compared. On histopathology ovarian dermoid cysts were found to contain tooth, hair, cartilage, bone, fat or even thyroid tissue which are derivatives of germ cell layers. The wall of cyst was composed of squamous epithelium. Data was collected through proforma and analyzed using SPSS version 20. Age and presence or absence of ovarian dermoid cyst on transabdominal sonogram and histopathology were used as variables. Mean and standard deviation were calculated for quantitative data i.e. age. Frequencies and percentages were calculated for qualitative data i.e., transabdominal sonography and histopathology results. To calculate sensitivity, specificity, PPV, NPV and accuracy of transabdominal ultrasonography a 2x2 table was constructed using the collected data.

RESULTS

In this study, out of 150 patients, 102 patients were found true positive (dermoid cyst present on both ultrasound and histopathology), 35 patients were true negative (dermoid cyst absent on both ultrasound and histopathology), while 05 patient were false positive

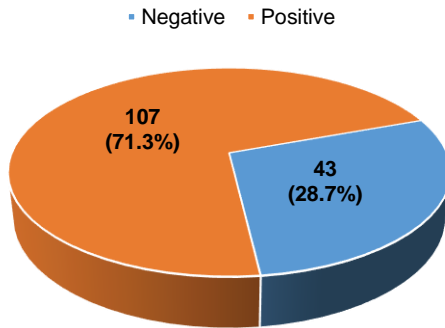


Figure 3. Distribution (frequency and percentage) of subjects by presence or absence of dermoid cyst on transabdominal sonography

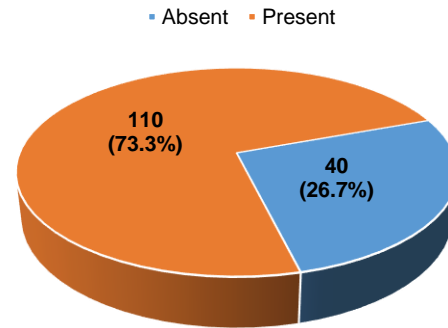


Figure 4. Distribution (frequency and percentage) of subjects by presence or absence of dermoid cyst on histopathology

(dermoid cyst present on ultrasound, absent on histopathology) and 08 patients were false negative (dermoid cyst absent on ultrasound and present on histopathology). When results of transabdominal ultrasound and histopathology were compared, sensitivity of TAS was found to be 92.7% with specificity of 87.5 % and diagnostic accuracy 91.3 % in detection of ovarian dermoid cyst. Positive predictive value was 95.3% and negative predictive value was 81.5%.

DISCUSSION

Sonography can accurately diagnose an ovarian dermoid cyst¹¹ which is a common germ cell neoplasm among young girls. Dermoid cyst of ovary usually do not produce symptoms until they become large and cause pain due to compression or torsion. The immediate accurate diagnosis of complication of dermoid cyst is mandatory for optimal treatment and preservation of fertility.

Transabdominal ultrasonography has well developed role in the accurate diagnosis of ovarian dermoid cyst. Dermoid cyst has distinct sonographic gray scale morphological features and can be divided into three types of morphologies on sonography one with fat fluid level, second nodular mural protrusions and third layering of floating debris.^{12,13} In this study, 150 patients had clinical suspicion of pelvic mass, 107 (71.8%) had dermoid cyst, while 43 patients (28.6%) had alternative diagnosis including haemorrhagic ovarian cyst, endometrioma, appendicitis, tubo-ovarian mass\hydrosalpinx. This is in concordance with recently done study by Levine et al that show they are important differentials/ alternative diagnosis in sonographically suspected cases of dermoid cyst.¹⁴

In this study age range of the patients is 06-25 with mean age of 13.74 ± 3.95 years which is in close accordance with previous studies.¹⁵ In this research there is a high incidence of dermoid cyst in adolescents and young adults i.e. 73.3% which is same to incidence found in literature (73.2%).¹⁵ In this study, out of 150 patients, 102 patients were found true positive, 35 patients were true negative, while 05 patient were false positive and 08 patients were false negative. The sensitivity of transabdominal sonography was 92.7% and specificity as 87.5%, which are close to the earlier study by Mais et al¹⁶ and Patel¹⁷ by using ultrasonography for the detection of dermoid cysts. These results also corresponds with many previous studies in the literature which proved that ultrasound sensitivity ranges from 50% to 94% and a specificity 82% to 99% in dermoid cyst diagnosis.

The diagnostic accuracy of sonography in this study was 91.3% along with positive and negative predictive values 95.3 % and 81.3% respectively. These results are close to the results of other studies which proved diagnostic accuracy of transabdominal ultrasound 98% and positive predictive value of 98%.¹⁸ Therefore, the results of our study showed high diagnostic accuracy and sensitivity of transabdominal ultrasound for diagnosis of ovarian dermoid cyst that is why, it can be reliably used as 1st line imaging for ovarian dermoid cyst diagnosis.

In spite of the benign nature of dermoid cyst they continue to grow in size.¹⁹ Surgical intervention in young girls may reflect concerns regarding possible adverse effects on their future fertility, tiresome follow ups or cyst related complications (torsion, rupture, infection, malignant transformation). Laparoscopic cystectomy is preferred method of treatment and associated with very low risk of postoperative

complications. For larger cysts (> 6 cm size) and dermoid cysts presenting with torsion laparotomy is done.¹⁹

CONCLUSION

This study has concluded results for our local population and found high incidence of dermoid cyst among adolescent and young girls. Transabdominal ultrasonography is an accurate and sensitive readily available first line imaging technique for the diagnosis of ovarian dermoid cyst. It greatly improves the accuracy of diagnosis of dermoid cyst and plays an integral role in detection of dermoid cyst and planning further management. It also avoids unnecessary radiation exposure due to CT imaging for further evaluation.

REFERENCES

1. Shin NY, Kim MJ, Chung JJ, Chung YE, Choi JY, Park YN. The differential imaging features of fat-containing tumors in the peritoneal cavity and retroperitoneum: the radiologic-pathologic correlation. *Korean J Radiol* 2010; 11: 333-345.
2. Lakhoo K. Neonatal teratomas. *Early Hum Dev* 2010; 86: 643-7.
3. Al Jama FE, Al Ghamdi AA, Gasim T, Al Dakhiel SA, Rahman J, Rahman MS. Ovarian tumors in children and adolescents—a clinical study of 52 patients in a university hospital. *J Pediatr Adolesc Gynecol* 2011; 24: 25-8.
4. Hasanzadeh M, Tabare S, Mirzaean S. Ovarian dermoid cyst. *Professional Med J* 2010; 17: 512-515.
5. Park SB, Kim JK, Kim KR, Cho KS. Imaging findings of complications and unusual manifestations of ovarian teratomas. *Radiographics* 2008; 28: 969-83
6. Amjad AI, Pal I. De novo primary squamous cell carcinoma of the ovary: a case of a rare malignancy with an aggressive clinical course. *J Pak Med Assoc* 2008; 58: 272-4.
7. Tongsong T, Luewan S, Phadungkiatwattana P, Neeyalavira V, Wanapirak C, Khunamornpong S et al. Pattern recognition using transabdominal ultrasound to diagnose ovarian mature cystic teratoma. *IJGO* 2008; 103: 99-104
8. Valentin L, Ameye L, Jurkovic D, Metzger U, Lécuru F, Van Huffel S, Timmerman D. Which extrauterine pelvic masses are difficult to correctly classify as benign or malignant on the basis of ultrasound findings and is there a way of making a correct diagnosis? *Ultrasound Obstet Gynecol* 2006; 27: 438-44.
9. Sandler MA, Silver TM, Karo JJ. Gray scale ultrasonic feature of ovarian teratomas. *Radiology* 1979; 131: 705-709.
10. Chapron C, Dubuisson JB, Samouh N, Foulot H, Aubriot FX, Amsquer Y, et al. Treatment of ovarian dermoid cysts. Place and modalities of operative laparoscopy. *Surg Endosc* 1994; 8: 1092-5.
11. Togashi K, Nishimura K, Itoh K, Fujisawa I, Sago T, Minami S, et al. Ovarian cystic teratomas: MR imaging. *Radiology* 1987; 162: 669-673.
12. Valentin L. Pattern recognition of pelvic mass by gray-scale ultrasound imaging: the contribution of Doppler ultrasound. *Ultrasound Obstet Gynecol* 1999; 14: 338-347.
13. O'Neill KE, Cooper AR. The approach to ovarian dermoids in adolescents and young women. *J Pediatr Adolesc Gynecol* 2011; 24: 176-80.
14. Levine D, Brown DL, Andreotti RF, Benacerraf B, Benson CB, Brewster WR, et al. Management of asymptomatic ovarian and other adnexal cysts imaged at US: Society of Radiologists in Ultrasound Consensus Conference Statement. *Radiology* 2010; 256: 943-54.
15. Alotaibi MO, Navarro OM. Imaging of ovarian teratomas in children: a 9-year review. *Can Assoc Radiol J* 2010; 61: 23-8.
16. Mais V, Guerriero S, Ajossa S, Angiolucci M, Paoletti AM, Melis GB. Transvaginal ultrasonography in the diagnosis of cystic teratoma. *Obstet Gynecol* 1995; 85: 48-52.
17. Patel MD, Feldstein VA, Lipson SD, Chen DC, Filly RA. Cystic teratomas of the ovary: diagnostic value of sonography. *AJR Am J Roentgenol* 1998; 171: 1061-5.
18. Malde HM, Kedar RP, Chadha D, Nayak S. Dermoid mesh: a sonographic sign of ovarian teratoma. *AJR Am J Roentgenol* 1992; 159: 1349-135
19. Hoo WL1, Yazbek J, Holland T, Mavrelou D, Tong EN, Jurkovic D. Expectant management of ultrasonically diagnosed ovarian dermoid cysts: is it possible to predict outcome? *Ultrasound Obstet Gynecol*. 2010 Aug;36(2):235-40.