

Diagnostic efficacy and suitability of trans-thoracic ultrasonography for pleural fluid detection – The future non-invasive gold-standard?

Abdul Rasheed Qureshi, Muhammad Irfan, Zeeshan Ashraf, Muhammad Amjad Ramzan, Tahmina Naeem, Huma Bilal

¹Assistant Professor, Gulab Devi Post Graduate Medical Institute Lahore, Pakistan, ²Chest Specialist, OPD, Gulab Devi Chest Hospital Lahore, Pakistan, ³Lecturer, Department of Statistics, Gulab Devi Educational Complex, Lahore, ⁴Medical Officer, Men Advisory Training Center, Sir Ganga Ram Hospital, Lahore, Pakistan, ⁵Women Medical Officer-Gulab Devi Teaching Hospital, Lahore

Correspondence to: Muhammad Irfan, Email: irfan16d2@gmail.com

ABSTRACT

Background: Conventionally Pleural effusions are suspected by history of pleuritis, evaluated by physical signs and multiple view radiography. Trans-thoracic pleural aspiration is done and aspirated pleural fluid is considered the gold-standard for pleural effusion. Chest sonography has the advantage of having high diagnostic efficacy over radiography for the detection of pleural effusion. Furthermore, ultrasonography is free from radiation hazards, inexpensive, readily available and feasible for use in ICU, pregnant and pediatric patients. This study aims to explore the diagnostic accuracy of trans-thoracic ultrasonography for pleural fluid detection, which is free of such disadvantages. The objective is to determine the diagnostic efficacy of trans-thoracic ultrasound for detecting pleural effusion and also to assess its suitability for being a non-invasive gold-standard.

Subject and methods: This retrospective study of 4597 cases was conducted at pulmonology OPD-Gulab Devi Teaching Hospital, Lahore from November 2016 to July 2018. Adult patients with clinical features suggesting pleural effusions were included while those where no suspicion of pleural effusion, patients < 14 years and pregnant ladies were excluded. Patients were subjected to chest x-ray PA and Lateral views and chest ultrasonography was done by a senior qualified radiologist in OPD. Ultrasound-guided pleural aspiration was done in OPD & fluid was sent for analysis. At least 10ml aspirated fluid was considered as diagnostic for pleural effusion. Patient files containing history, physical examination, x-ray reports, ultrasound reports, pleural aspiration notes and informed consent were retrieved, reviewed and findings were recorded in the preformed proforma. Results were tabulated and conclusion was drawn by statistical analysis.

Results: Out of 4597 cases, 4498 pleural effusion were manifested on CXR and only 2547(56.62%) pleural effusions were proved by ultrasound while 2050 (45.57%) cases were reported as no Pleural effusion. Chest sonography demonstrated sensitivity, specificity, PPV, NPV and diagnostic accuracy 100 % each.

Conclusions: Trans-thoracic ultrasonography revealed an excellent efficacy that is why it can be considered as non-invasive gold standard for the detection of pleural effusion.

Keywords

Trans-thoracic sonography, Pleural Effusion, Diagnostic Accuracy.

INTRODUCTION

Pleural effusions are common in daily pulmonology practice. About 50-70% cases are tubercular, because of high incidence of tuberculosis in endemic areas like Pakistan. ¹⁻² Malignancy, acute infection and connective tissue disorders are also significant contributors.³ Patients usually present with shortness of breath, chest pain and pyrexia of unknown origin. Physical

examination shows decreased chest movement, stony-dull percussion note and decreased or absent air-entry on the affected side.⁴⁻⁶ The X-Ray Chest PA and Lateral views are the traditional first-line investigations to evaluate pleural effusion because the fluid accumulates first in of posterior costo-phrenic angle, which is obliterated by 50 ml pleural effusion.⁷ Similarly 150-200 ml pleural effusion is required to obliterate lateral CP angle on PA view and 500 ml pleural effusion is sufficient to obliterate the diaphragmatic silhouette.⁷⁻⁸ Chest x-ray (CXR) PA film can miss small pleural effusion. Supine chest film can miss even a larger effusion because the fluid gravitates to the dependent parts but such effusions can be readily picked by CT, ultrasound or lateral decubitus radiographs.⁹⁻¹⁰ The exposure to ionizing radiations carries a measurable

Conflict of Interest: The authors declared no conflict of interest exist.

Citation: Qureshi AR, Irfan M, Ashraf Z, Ramzan MA, Naeem T, Bilal H. Diagnostic efficacy and suitability of trans-thoracic ultrasonography for pleural fluid detection – The future non-invasive gold-standard? J Fatima Jinnah Medical Univ. 2019; 13(4): 184-190.

DOI: <https://doi.org/10.37018/jfjmu.588>

risk which preclude the frank use of x-ray and CT-scan in pregnancy and young children.¹¹ In critically ill patients, CXR is performed at the bedside, using portable machine but the limitations constrain its usefulness. The bedside x-ray films are usually of poor quality with low sensitivity and even more than 30% of the X-ray films are considered suboptimal.¹² Furthermore, it is frequently difficult to obtain PA and Lateral projections in critically-ill patients. Despite these limitations, bedside chest x-ray remains the daily reference for imaging. In such situations, trans-thoracic ultrasound has emerged as a new horizon in the world of pulmonology.¹³ It is under used in clinical practice because it is inadequately understood. Many physicians are still of the opinion that ultrasonography of chest is not feasible because of the presence of air in the lungs which interferes with the penetration of ultrasound waves. On the other hands, modern researchers have proved that trans-thoracic ultrasound is an excellent modality capable of identifying even physiologic amounts of pleural fluid. In addition, invasive procedures can also be conducted safely under real-time guidance. Recent studies have demonstrated its efficiency in detecting and quantifying pleural effusions. 05—10 ml pleural fluid can be diagnosed with good accuracy.¹⁴⁻¹⁵ This procedure is easy to perform in operation theatre, emergency room, or ICU, by the bed-side. Moreover, it is cost effective, readily available, free of the hazards of ionizing radiations and provides real-time guidance for aspiration of pleural fluid, inter-costal tube placement and percutaneous biopsy of pleural lesions, that is why it is an important tool in a pulmonology clinic.¹⁶⁻¹⁸ The main limitations are that it is operator dependent, gives less panoramic view than x-ray film and surface imaging technique.¹⁹⁻²⁰ We conducted this study to determine the diagnostic efficacy of trans-thoracic ultrasonography for pleural fluid detection and its suitability for being a non-invasive gold-standard.

SUBJECTS AND METHODS

This retrospective study was conducted at the Pulmonology OPD-Gulab Devi Teaching Hospital, Lahore-Pakistan from November 2016 to July 2018. The study was ethically approved by the IRB of the hospital vide No. Admin/GDEC/18.1107 and 4597 adult patients with 14-89 years of age, suggesting pleural effusion on history and physical examination were included. While those without any suspicion of pleural effusion, pregnant patients and young children (<14 years) were excluded. All patients were evaluated

with detailed history and physical examination by senior physicians of OPD. X-ray chest PA & Lateral views were obtained. The patients suggesting pleural effusion, on the bases of clinical and radiographic findings were sent for trans-thoracic ultrasound.

Radiographs were evaluated by an experienced radiologist for the presence or absence of pleural effusion. Obliteration of costo-phrenic angle (CP), diaphragm and homogenous peripheral opacity with C-shaped upper surface meniscus were considered for radiological diagnosis of pleural effusion. Pleural effusions were classified as minimal if CP angle were blunted and small when CP angle was obliterated. If C-shaped meniscus obliterated the entire hemi-diaphragm, effusion was labeled as large. The patients were evaluated with Sonovista-fx (Siemens) machine, using 3.5—5.5 MHZ convex transducer. Ultrasound scanning was done, systematically on both sides, anteriorly, posteriorly and laterally both in sitting and supine positions by a qualified & senior radiologist with at least 25 year experience. Pleural effusions, pleural thickening, septations and loculations were identified accurately. Consolidation, normal pleurae, pleuro-pulmonary & mediastinal masses and lung abscess was diagnosed with confidence. Mediastinal lymphadenopathy, masses and cysts were efficiently detected. Empyema, lung collapse and hydro-pneumothorax were diagnosed successfully by ultrasound and further confirmed by the OPD-physicians using bronchoscopy, CT-scanning, pleural tap and thoracoscopy. An informed consent was obtained and Real-time ultrasound-guided pleural aspiration was done in pleural effusion cases and aspirated pleural fluid was considered as diagnostic. FNAC & biopsy procedures were also done under ultrasound-guidance. Trans-thoracic scanning revealed four sonographic patterns: (1) An-echoic - Simple pleural effusion without any internal echoes, (2) Complex-septated - complex pleural effusion containing internal septations, (3) Complex non-septated - complex pleural effusion without any internal fibrous strands and (4) Homogeneously echogenic effusion - pleural effusion consisting of homogenous bright echoes inside.

For the purpose of quantification, pleural effusion (PE) less than 50 ml was labeled as minimal pleural effusion which was unable to be aspirated and pleural effusion up-to 300ml were classified as mild, similarly up to 1000 ml was labeled as moderate while more than 1000 ml effusion was classified as massive pleural effusion.

Medical records of the patients with pleural effusion, containing history, physical examination notes, x-rays, ultrasound reports, ultrasound guided aspiration notes, and laboratory reports were retrieved and reviewed retrospectively. Clinical, radiological and interventional findings were recorded in a preformed proforma. Facts were organized, tabulated and statistical analysis was performed to reach the conclusion.

SPSS-16 software package was utilized for statistical evaluation. Quantitative data was expressed by mean and + standard deviation. Categorical data was presented as frequency. Efficacy was measured in percentage with precision at 95% confidence interval. Fisher Exact test was used for comparison and *p*-value < 0.05 was considered significant.

RESULTS

4597 patients with age 14 to 89 years showed mean age 37.8 years with SD+19.46 years. There were 3021 (65.69%) male patients while 1576 (34.28%) patients were female with male to female ratio 1.91:1. Table 1 summarizes the clinical presentation of 4597 patients. Cough, fever and chest pain were the main presenting complaints in majority of the patients. The detail of physical signs observed in study population are depicted in Table 1. Total 4498 patients showed evidence of pleural effusion on chest x-ray PA & Lateral views. In 76 cases of pleural effusion (sub-pulmonic pleural effusion), chest x-ray was clear. Further 23 cases, which were reported as pulmonary masses on CXR were diagnosed as encysted pleural effusions by sonography. Pleural effusion was reported in 2547 of 4597 patients (55.40%) by chest sonography while 2050 of 4597 cases (44.59%) were reported as “no pleural effusion seen”. Total 1212 (47.58%) pleural effusions were seen on the right side, 987(38.75%) left sided while 348 (13.66%) pleural effusions were bilateral. The detailed quantification is presented in Figure 1. The frequency of homogenous echogenic, simple anechoic, complex non-septated and complex septated pleural effusions are depicted in Figure 2 while frequency of pleural effusion ruled-out cases are clearly explained in Table 1.

Total of 4498 cases of pleural effusion were reported on x-ray chest, while 76 cases of subpulmonic Effusions were not manifested on CXR and it appeared clear. On the other hand 23 cases of encysted pleural effusion were picked up as pulmonary mass lesions on CXR. In this way, we had total registered cases (4498 + 76 + 23) = 4597. Ultrasound guided successful pleural aspiration revealed pleural effusion in 2547 (2448 + 76 +

23) cases while 2050 cases showed no pleural effusion at all. By considering ultrasound guided successful pleural aspiration as the “Gold Standard”, for diagnostic yield of CXR, we have True positive cases (TP) = 2448, False positive (FP) cases = 2050, True negative (TN) cases= 00 and False negative cases (FN) = (76 + 23) = 99. The results of statistical analysis about efficacy are detailed in Table 2. Similarly, for diagnostic yield of trans-thoracic ultrasound, we have TP = 2547 cases, FP cases = 0 .00 cases, TN= 2050 cases and FN = 00.00 cases. The calculated value for sensitivity, specificity, PPV, NPV and diagnostic accuracy was 100.00% for each parameter, the detail is depicted in Table 2. By comparing the efficacy of chest x-ray and ultrasonography, the Fisher exact test statistic value is < 0.00001. The result is significant at *p*<0.05.

Table 1. Frequency of signs and symptoms and radiographic pleural effusions excluded by ultrasound

Characteristics	Observed cases	Percentage
Clinical presentation		
Cough	3402	74.00 %
Fever	3034	65.99 %
Chest pain	2942	64.04 %
Shortness of breath	2482	53.99 %
Expectoration.	1093	23.77 %
Contact history	828	18.01 %
Physical signs [n = 4597]		
Decreased chest movement & expansion	3664	79.70 %
Decreased / absent breath sounds	3044	68.39 %
Reduced vocal fremitus	3040	66.13%
Dull percussion note	2942	64.04 %
Bulged chest wall	1559	33.91 %
Use of accessory muscles of resp.	322	7.00 %
Pleural rub.	294	6.39 %
Clubbing	508	11.05 %
Ultrasound features [n=2050]		
Normal pleurae	1072	52.29%
Pleural thickening	403	19.65 %
Consolidation.	364	17.75 %
Pleuro-phrenic adhesions	107	5.21 %
Lung abscess	43	2.09 %
Collapse	29	1.41 %
Lung mass	24	1.17 %
Destroyed lung	06	0.29 %
Hydatid cyst	02	0.09 %

Table 2. Comparative efficacy by CXR and ultrasound [n = 4597]

Statistical test	X-Ray (95% CI)	Ultrasonography (95% CI)
Sensitivity	96.11% (95.29 to 96.83)	100% (99.8% to 100%)
Specificity	00.00% (0.0 to 0.18)	100% (99.8% to 100%)
PPV	54.42% (54.2 to 54.6)	100%
NPV	00.00%	100%
Diagnostic accuracy	53.2 (51.8% to 54.7%)	100% (99.9% to 100%)

Abbreviations: CI: Confidence interval

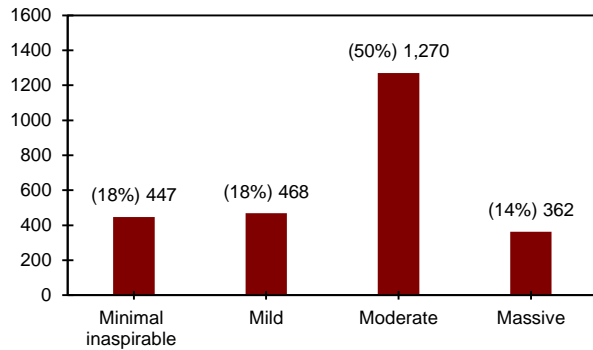


Figure 1. Quantification of pleural effusions by ultrasound

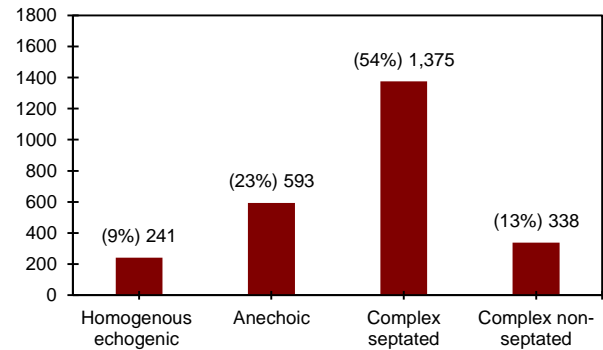


Figure 2. Qualitative distribution of pleural effusions

DISCUSSION

Patients with 14-89 years age participated in the study. Mean age was 37.8 with Std. Deviation + 19.46. Ibrahim and co-authors reported the mean age 31.5 years while Denise Duprat Neves reported the mean age as 33.76 years, these results are quite comparable with those of current study.²¹ In this study, 3021 patients (65.69)% patients were male while 1576 were (34.28%) female. Male to female ratio was 1.91:1. Pleural effusion was more common in male than in female, in local community. These findings are comparable to previous study.²²

Chest radiography is considered next to inspection, palpation, percussion and auscultation for the detection of pleural effusion. If chest x-ray is suggestive, a needle is put into the pleural space and aspirated fluid confirms the diagnosis of pleural effusion, otherwise modern methods are deployed for alternative diagnosis. Several times, chest x-ray suggests pleural effusion, but negative thoracentesis makes diagnosis uncertain. When the same case is examined by ultrasound or CT, pleural effusion is detected. Many times, no pleural effusion is identified even by using these modalities. It is due to the fact that the bulky patients, especially females, skin folds or breast shadows overlying costo-phrenic angles manifest as effusion on CXR. Furthermore, basal segmental consolidation, collapse, cyst or mass occupying costo-phrenic angle area, also manifest as pleural effusion on radiograph. Especially pleural thickening and consolidation is the most common culprit behaving as effusion on CXR.²³ Some positional and film processing artefacts may also create the false impression of pleural effusion on chest radiograph. Because, ultrasound has very high sensitivity for the fluid even more than that of CT that is why even minute amount of pleural effusion is not missed by this modality.²⁴

The current study revealed that out of 4597 cases only 2547 patients were found with pleural effusion while 2050 cases were reported as “No pleural effusion seen”. It is worth noting that these cases were declared as pleural effusion by x-ray chest but ultrasound scanning not only rejected the false impression, rather unveiled the accurate diagnosis. Although physical examination suggested these cases as pleural effusion but it has low sensitivity and specificity, in addition, physical signs may be helpful to rule out not to rule in the pleural effusion.⁶ Similarly, Light R. reported that PA-chest radiographs are not sensitive for the detection of pleural effusions until 200ml of fluid has accumulated. Therefore, CXR-PA film can miss small pleural effusion. Supine chest x-ray film can miss even a larger effusion because the fluid gravitates to the dependent parts and its image blends with that of posterior chest wall. Such effusion can be picked readily by ultrasound, CT or a lateral decubitus chest film. 23-cases of pulmonary opacities with suspicion of mass lesion were correctly diagnosed as encysted pleural effusions by ultrasound.²⁵

In this study, 403 cases diagnosed as pleural effusion by CXR were clearly declared that it was the pleural thickening not the pleural effusion by ultrasound. In this way, ultrasound rightly diagnosed, pleural thickening, mimicking pleural effusion which otherwise were at the risk of consideration of pleural effusion on every future CXR examination. Normal visceral and parietal pleurae are opposed and measure 0.2–0.3mm. By detecting pleural thickening, a clear-cut line has been drawn between the normal and thickened pleurae. This study shows that by detecting homogenous echogenic effusions, empyema, hemothorax or pyo-pneumothorax were suggested. The finding of sonographic septations, predicted tuberculosis, nodular pleural thickening and positive

swirling sign pointing towards a mitotic process, further narrowed down the differential diagnosis.

Pleural ultrasound is capable of detecting as small as 5ml, but a volume as small as 20ml is more reliably identified and ultrasound is 100% sensitive for effusions >100ml.²⁶⁻²⁷ In addition, Color Doppler ultrasound is capable of differentiating even minute pleural effusions from solid pleural abnormalities with high degree of confidence²⁸.

Biostatistics for the diagnostic yield, revealed very high efficacy of ultrasound (Table 2) as compared to conventional chest x-ray with sensitivity, specificity, PPV, NPV and diagnostic accuracy of 100 % each. These results are similar to those reported by Ibrahim I. Elmahalawy and group who stated that lung ultrasound had a sensitivity of 94%, specificity of 96%, PPV of 97% and NPV of 90% for pleural effusion.²⁹ The current study results are also comparable to those of M. Rocco and co-authors who reported a sensitivity of 94% and specificity of 99% for ultrasound based detection of pleural effusion while CXR had a sensitivity of 42% and a specificity of 97% in diagnosis of pleural effusion.³⁰ Similarly, the efficacy reported by K. Sikora and associates displayed that chest radiography had a sensitivity of 65%, a specificity of 81% while ultrasound had a sensitivity of 100%, a specificity of 100%, and a diagnostic accuracy of 100% which exactly coincides with that of current study results.³¹ Furthermore, a highly significant p-value ($p < 0.00001$) shown by the current study, revealed a wide gap between the diagnostic efficacies of the two modalities.

Although CXR has high sensitivity for pleural effusion yet lacks specificity. It is practically unable to differentiate among pleural effusion, pleural thickening and collapse. On the other hand, it has the advantage of providing the panoramic view in contrast to ultrasound which is a surface imaging modelity. That is why pleural effusion and cardiomegaly or mediastinal mass lesions were diagnosed in just single glance. Similarly pulmonary infiltrate if associated with pleural effusion are readily picked-up by CXR than by ultrasound chest. Bony lesions like dysplasia, fracture and focal defects are best shown by CXR than ultrasound. Sub-pulmonic pleural effusions are difficult to be picked by CXR but very easy to be detected by ultrasound. Chest ultrasound can be utilized in ICU or in any ward as point of care tool with great degree of confidence.³²⁻³⁵

Additionally, ultrasound provided real-time guidance for pleural aspiration, intercostal tube placement, FNAC and biopsy procedures. It is also

utilized for selection of point of aspiration which prevented possible accidental organ puncture.³¹ Not only the pleural fluid sampling success rate has been shown to be increased tremendously by ultrasound guidance, also the possibility of wrong site and wrong side has totally been eliminated by real-time guidance.³² It is because, various centers recommend, all pleural aspirations, be performed under ultrasound guidance.

It is clear from above discussion that ultrasonography is really an excellent modality which not only identify & quantify a pleural effusion, also throws light on underlying disease process. It is, therefore, suggested that all cases with CXR indicating or suspecting pleural effusion, be subjected to ultrasonography before putting a needle inside for aspiration. It eliminates ultimately the chances of wrong side, wrong site and accidental organ puncture.

This study results can find positive application in resource-limited areas where CXR, CT Scan and Pleuroscopic facilities are not available, just an ordinary portable ultrasound machine is sufficient to reproduce the results. As during the management of pleural effusion, x-ray exposure are repeated (pre-procedure, post-procedure and follow up) which are not safe in children and pregnant patients due to the hazards of ionizing radiations. Similarly, HDU, ICU and unconscious patients with a number of gadgets attached, cannot be easily mobilized to or managed in radiology department. Trans-thoracic ultrasound is a blessing for all these situations. If it is considered the modality of choice for detection of pleural effusion, it can save all patients from multiple exposures of ionizing radiations. As pleural effusion is proved after pleural aspiration clinically, which is an invasive procedure. Chest ultrasound is indeed a non-invasive tool, doing the same job.

The only limitation of this study is that it is a single center study, but adequate sample size increases the power of this study. Trans-thoracic ultrasonography is quite new in our medical community and gaining understanding and popularity slowly and gradually. Furthermore, it also depends upon the expertise of the operator. With the passage of time, more and more people will opt it, get experience and studies from multiple centers will come out.

Various modalities like CXR, CT-scan and thoracoscopy had been in use as gold standard for pleural fluid detection in different situation, depending upon the availability. Clinically, aspirated pleural fluid is being considered as gold standard for pleural effusion.^{23,33}

As real-time imaging of pleural effusion is almost equivalent to aspirated pleural fluid, being non-invasive, it has the full potential to be considered as a non-invasive gold standard for the detection of pleural effusion.

CONCLUSION

Trans-thoracic ultrasonography is a valuable modality, having high efficacy, excellent feasibility & safety, and can be considered a non-invasive gold standard for the detection of pleural effusions. It can be used with confidence for pregnant, pediatric and ICU patients as point of care modality.

Acknowledgements: The authors are thankful to Dr. Ayesha, Dr. Ahmer, Dr. M. Jameel, Dr. Hamid Mehmood, Nemat Ali, Muhammad Tahir and Mehfooz Ahmed for their co-operation through-out the study.

REFERENCES

- Fatima R, Harris RJ, Enarson DA, Hinderaker SG, Qadeer E, Ali K, et al. Estimating tuberculosis burden and case detection in Pakistan. *Int J Tuberc Lung Dis*. 2014; 18(1):55-60.
- Light RW. Update on tuberculous pleural effusion. *Respirology*. 2010; 15:451-458. DOI: <https://doi.org/10.1111/j.1440-1843.2010.01723.x>
- Porcela JM, Esquerdab A, Vivesc M, Bielsaa S. Etiology of pleural effusions: Analysis of more than 3,000 consecutive thoracenteses. *Arch Bronconeumol*. 2014; 50(5):161-165.
- Diaz-Guzman E, Budev MM. Accuracy of the physical examination in evaluating pleural effusion. *Cleve Clin J Med*. 2008; 75(4):297-303.
- Guarino JR, Guarino JC. Auscultatory percussion: A simple method to detect pleural effusion. *J Gen Intern Med*. 1994;9(2):71-74.
- Kalantri S, Joshi R, Lokhande T, Singh A, Morgan M, Colford JM Jr, et al. Accuracy and reliability of physical signs in the diagnosis of pleural effusion. *Respir Med*. 2007;101(3):431-438.
- Psallidas I, Kalomenidis I, Porcel JM, Robinson BW, Stathopoulos GT. Malignant pleural effusion: From bench to bedside. *Eur Respir Rev*. 2016; 25(140):189-198.
- Mandovra N, Vaidya PJ, Chhajed PN. Current approaches to tuberculous pleural effusion. *Astrocyte*. 2017;4:87-93.
- Moffett BK, Panchabhai TS, Nakamatsu R, Arnold FW, Peyrani P, Wiemken T, et al. Comparing posteroanterior with lateral and anteroposterior chest radiography in the initial detection of parapneumonic effusions. *Am J Emerg Med*. 2016; 34, 12, 2402-2407.
- Mohammad F, Mohamed A, Khawja S, Rubinfeld I, Hammoud Z. Efficacy of portable ultrasound to detect pneumothorax post lung resection. *J Radiol Med imaging*. 2018;2:1007.
- Oks 1, Cleven KL, Cardenas-Garcia J, Schaub JA, Koenig S, Cohen RI, et al. The effect of point-of-care ultrasonography on imaging studies in the medical ICU: A comparative study. *Chest*. 2014;146(6):1574-1577.
- Yan C, Hui R, Lijuan Z, et al Lung ultrasound vs. chest X-ray in children with suspected pneumonia confirmed by chest computed tomography: A retrospective cohort study. *Experimental and Therapeutic Medicine*, 2020; 19, 1363-1369. DOI: <https://doi.org/10.3892/etm.2019.8333>.
- Rouby JJ, Arbelot C, Gao Y, Zhang M, Lv J, An Y, et al. Training for lung ultrasound score measurement in critically ill patients. *Am J Resp Crit Care Med*. 2018; 198:398-401.
- Faheem MH. Is transthoracic ultrasound (TUS) a reliable predictor of the nature of pleural and peripheral pulmonary lesions? Correlation with cyto-histological findings. *Egypt J Radiol Nucl Med*. 2019; 50, 4. DOI: <https://doi.org/10.1186/s43055-019-0004-0>
- Kang HK, So HJ, Kim DH, Koo HK, Park HK, Lee SS, et al. The use of lung ultrasound in a surgical intensive care unit. *Korean J Crit Care Med*. 2017;32(4):323-332.
- Steppan D, DiGiusto M, Steppan J. Perioperative lung ultrasound in the pediatric intensive care unit—Beyond the vasculature and parenchyma. *J Cardiothorac Vasc Anesth*. 2020; 34(4):956-958.
- Qureshi AR, Mehmood H, Irfan M, Mushtaq A, Mushtaq H. Ultrasound assisted pleural biopsy with Abram needle is a valuable tool in diagnosing exudative lymphocytic pleural effusions. *Ann Pak Inst Med Sci*. 2018;14(1):58-63.
- Khan RA, Kumar V, Taimur M, Khan MA, Arshad MM. Diagnostic yield of ultrasound-guided trucut biopsy in diagnosis of peripheral lung malignancies. *Cureus*. 2019; 11(6): e4802.
- Qureshi AR, Ahmed AUKA. Diagnostic value and safety of ultrasound-guided needle biopsy in evaluation of peripheral lung and mediastinal nodules. *JFJMU*. 2017;11(3):40-45.
- McCracken DJ, Laursen CB, Barker G, Gleeson FV, Cullen KM, Rahman NM. Thoracic ultrasound competence for ultrasound-guided pleural procedures. *Eur Respir Rev*. 2019; 28(154): 190090.
- Neves DD, Dias RM, Cunha AJLA. Predictive model for the diagnosis of tuberculous pleural effusion. *Braz J Infect Dis*. 2007; 11(1):83-88.
- Valdés L, San José ME, Pose A, Gude F, González-Barcala FJ, Alvarez-Dobaño JM et al. Diagnosing tuberculous pleural effusion using clinical data and pleural fluid analysis: A study of patients less than 40 years-old in an area with a high incidence of tuberculosis. *Respir Med* 2010;04 (8):1211-1217.
- Buonsenso D, Pata D, Chiaretti A. COVID-19 outbreak: less stethoscope, more ultrasound. *The Lancet Respiratory Medicine*. 2020;8(5):e27.
- Na MJ. Diagnostic tools of pleural effusion. *Tuberculosis and respiratory diseases*. 2014;76(5):199-210.
- Brogi E, Gargani L, Bignami E, Barbario F, Marra A, Forfori F, et al. Thoracic ultrasound for pleural effusion in the intensive care unit: A narrative review from diagnosis to treatment. *Critical Care*. 2017;21(1):325.
- Arbelot C, Neto FLD, Gao Y, Brisson H, Chunyao W, Lv J, et al. Lung ultrasound in emergency and critically ill patients number of supervised exams to reach basic competence. *Anesthesiology*. 2020;132(4):899-907.
- Joshi P1, Vasishta A1, Gupta M1. Ultrasound of the pediatric chest. *J Radiol*. 2019; 92(1100):20190058. DOI: <https://doi.org/10.1259/bjr.20190058>.
- Hasan AA, Makhlof HA, Mohamed AR. Discrimination between pleural thickening and minimal pleural effusion using color Doppler chest ultrasonography. *Egypt J Chest Dis Tuberc*. 2013;62(3):429-433.
- Elmahalawy II, Doha NM, Ebeid OM, Abdel-Hady MA, Saied O. Role of thoracic ultrasound in diagnosis of pulmonary and pleural diseases in critically ill patients. *Egypt J Chest Dis Tuberc*. 2017;66(2):261-266.
- Rocco M, Carbone I, Morelli A, Bertolotti L, Rossi S, Vitale M et al, Diagnostic accuracy of bedside ultrasonography in the ICU: Feasibility of detecting pulmonary effusion and lung

- contusion in patients on respiratory support after severe blunt thoracic trauma. *Acta Anaesthesiol Scand*. 2008;52(6):776-784.
31. Sikora K, Perera P, Mailhot T, Mandavia D. Ultrasound for the detection of pleural effusions and guidance of the thoracentesis procedure. *Int Sch Res Notices*. 2012;2012.
 32. Ali NM, Maguid H, Gamil NM, Tawfeek MM, Hegab SS. Evaluation of the role of bedside lung ultrasound versus chest X-ray in critically ill patients. *Zagazig University Medical Journal*. 2019;25(6):887-897.
 33. Sorensen B1, Hunskaar S2,3. Point-of-care ultrasound in primary care: a systematic review of generalist performed point-of-care ultrasound in unselected populations. *Ultrasound J*. 2019;11(1):31.
 34. Mumtaz U, Zahur Z, Chaudhry MA, Warraich RA. Bedside Ultrasonography: a useful tool for traumatic pneumothorax. *J Coll Physicians Surg Pak*. 2016;26(6):459-462.
 35. Qureshi AR, Irfan M, Khan AU. Role of pleural ultrasonographic diagnosis in treatment planning: A study of 3831 cases. *J Fatima Jinnah Med Univ*. 2018;12(4):146-151.