

# Internal limiting membrane peel with or without finesse flex loop assistance

Faisal Mehmood<sup>1</sup>, Abdullah Irfan, Awais Afzal<sup>2</sup>, Muhammad Moin<sup>3</sup>, Muhammad Muneeb<sup>4</sup>

<sup>1</sup>PGR Trainee, Lahore General Hospital, Lahore, <sup>2</sup>PGR Trainee, Lahore General Hospital, Lahore, <sup>3</sup>PGR Trainee, Lahore General Hospital, Lahore, <sup>4</sup>Head of Department, Ophthalmology Lahore General Hospital, Lahore, <sup>5</sup>PGR Trainee, Lahore General Hospital, Lahore

**Correspondence to:** Dr. Faisal Mehmood, Email: dr.faisalmehmood83@gmail.com

## ABSTRACT

**Background:** Internal Limiting Membrane (ILM) peeling, currently, due to more successful hole closure rate and prevention of postoperative reopening, has been accepted globally but it may leads to other trivial complications like subretinal and retinal hemorrhage, vitreous hemorrhage and retinal edema etc., which may be avoided by using adjuvant instruments, like Finesse flex Loop. The aim of this study was to compare complications after ILM peel, with and without finesse loop.

**Patients and methods:** In this comparative cross-sectional study conducted in Ophthalmology Department of Lahore General Hospital, Lahore from February 2018 to January 2019, the data of thirty (30) patients was compared after taking informed consent through self-made pro-forma. Data analysis was done on SPSS-21. Frequency / percentage table of qualitative variables like retinal hemorrhage, retinal tear, retinal detachment and surface irregularities were designed by using excel-16. **Fischer's exact** test was applied to compare complications after ILM peeling with and without using Finesse loop. Confidence interval of 0.95 with  $\alpha$  of 0.05 was taken as significant.

**Results:** This study included thirty (30) patients (female: 13; male: 17) with mean age of 56 years and 8 months. **Comparison between outcomes of ILM peeling with and without using Finesse™ Flex Loop** showed that there is statistically non-significant difference in occurrence of retinal hemorrhage ( $p=0.245$ ), retinal tear ( $p=0.224$ ), retinal detachment ( $p=1.00$ ) and surface irregularities ( $p=0.39$ ). However, the prevalence of complications like surface irregularities, retinal tear, retinal hemorrhage and retinal detachment with finesse loop were less as compared to without finesse loop.

**Conclusion:** The prevalence of complications during ILM peel with finesse loop in a macular hole surgery, were less than that in ILM peel with ILM forceps alone.

### Keywords:

Macular Hole; Epiretinal Membrane; Internal Limiting Membrane; Finesse Loop

## INTRODUCTION

Macular hole (MH) can be defined as tear or defect in foveal retina which involves its full thickness from internal limiting membrane (ILM) to the outer segment of photoreceptor layer.<sup>1,2</sup> The incidence of macular hole has been reported to be 6.7 per 100,000 annually with 3:1 female to male ratio. Firstly, to close macular hole, a previously known untreatable cause of central vision distortion, Kelly and Wendel introduced a surgical procedure in 1991.<sup>3,4</sup> In literature, besides other techniques, peeling the ILM also worth noted to improve hole closure rate.<sup>5,6</sup>

ILM peeling, currently, due to more successfully hole closure rate and preventing postoperative reopening, has been accepted globally.<sup>7,8</sup> Late

reopening of macular hole is one of the most common postoperative complication of MH surgery.<sup>9-11</sup> Many techniques have been used to relieve this traction after marking ILM and allowing it to be peeled without indirect retinal damage. ILM peeling, the critical step is to create ILM flap to allow the peel to be started. For this purpose, different instruments (including picks and microvitreoretinal blades) have been designed to do this. A recent local study by Khaqan and coauthors demonstrates that ILM peeling assisted by brilliant blue stain shows promising results.<sup>12</sup> Recently, a microserrated nitinol loop (Finesse Flex Loop) of variable length, and hence stiffness, has been introduced for the same purpose. Direct "pinch" technique using forceps to do this is also used by many ophthalmologists.<sup>13</sup> The finesse flex loop designed for ILM peeling, is a recently food and drug administration cleared membrane peeling instrument.<sup>14,15</sup> The Finesse flex loop is effective in providing an optimal scraping force and minimal retinal trauma to accurately peel desired area of ILM.<sup>16</sup> This study compares the

**Competing interests:** The author declares no competing interests exist.

**Citation:** Mehmood F, Irfan A, Afzal A, Moin M, Muneeb M. Internal limiting membrane peel with or without finesse flex loop assistance. *J Fatima Jinnah Med Univ.* 2020; 14(2): 64-67.

DOI: <https://doi.org/10.37018/tqqv9443>

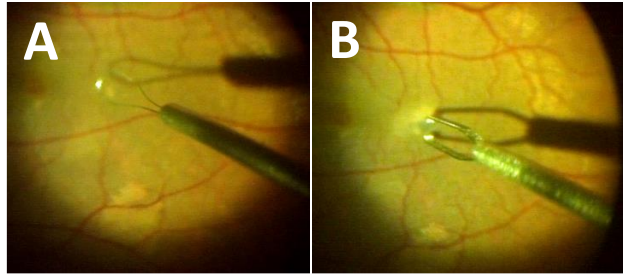


Figure 1: A) ILM peeling using Finesse Loop. B) ILM Peeling without Finesse Loop (with Forcep only).

common complications after ILM peel with and without finesse loop assistance.

### PATIENTS AND METHODS

In this prospective comparative cross-sectional study, 30 patients (including 13 females and 17 males) visiting Ophthalmology Department of Lahore General Hospital, Lahore (LGH) during February 2018 to January 2019 were recruited to this study after taking informed consent. The participants were divided into Group A (with finesse loop) and Group B (without finesse loop). Patients with full thickness macular hole (FTMH) and primary epiretinal membrane (ERM) were included and those with lamellar holes, secondary and iatrogenic ERM's were excluded from the study. 23G pars planavectomy and ILM staining with brilliant blue was performed by a 2<sup>nd</sup> year PGR (vitreo-retina). ILM peeling was done to relieve tangential traction for closure of macular hole. This was done with the help of finesse loop in half of the patients, while without finesse loop (with forceps only) in other half of patients (Figure 1A and B). The complications like retinal surface irregularities, retinal tear, retinal hemorrhage and retinal detachment were observed during surgery and after 1<sup>st</sup> post-operative week.

Data was entered and analyzed in SPSS-21. Table was designed on Excel-16. Fischer's exact test was applied to compare complications after ILM peeling with and without using Finesse loop. Confidence interval of 0.95 with  $\alpha$  of 0.05 was taken as significant.

### RESULTS

Out of 30 patients, 13 were female (43.33%) and 17 (56.67%) were male. Mean age of the patient was 56 years and 8 months. The results showed that there is statistically non-significant difference in occurrence of retinal hemorrhage ( $p=0.245$ ), retinal tear ( $p=0.224$ ), retinal detachment ( $p=1.00$ ) and surface irregularities ( $p=0.39$ ) (Table 1). Out of 30 patients, retinal hemorrhage was reported in only 3 (20%) patients undergoing ILM peeling with Finesse loop, whereas, it

Table 1. Outcome of ILM peel with or without finesse loop assistance

Outcome	With finesse loop	Without finesse loop	p-value*
Retinal haemorrhage	3 (20%)	7 (46.7%)	0.245
Retinal tear	0 (0.0%)	3 (20%)	0.224
Retinal detachment	0 (0.0%)	1 (6.7%)	>0.05
>Surface irregularities	2 (13.3%)	5 (33.3%)	0.39

\*A p-value of  $\leq 0.05$  was taken as significant.

is found in 7 (46.7%) patients in which peeling was done without Finesse loop. Similarly, retinal tear and retinal detachment were not found in any patient undergoing surgery using Finesse loop but in contrast 20% and 6.7% patients came with retinal tear and retinal detachment, respectively, among those who had undergone surgery without using finesse loop. Surface irregularities were noticed in 13.3% patients who had undergone surgery using finesse loop and in 33.3% patients in whom surgery was done without finesse loop assistance. Table 1 shows the comparison between outcomes of ILM peeling with and without using finesse loop.

### DISCUSSION

ILM peeling is among the most challenging surgical procedures in ophthalmology and has a potential detrimental consequence, not least of which relate to the surgeon learning curve. RNFL damage, retinal hemorrhages and full thickness retinal defects can be caused by instrumental trauma at the start of surgery and at ILM pickup point, whereas iatrogenic eccentric holes have also been reported. This study elaborates that the number of complications during ILM peel with finesse loop in a macular hole surgery were much less in comparison with performing ILM peel with ILM forceps alone. In a study by Ripandelli and coworkers it was seen that group in which ILM peeling was not done showed better outcomes than the group in which ILM peeling was done with old conventional technique using only forceps, as measured by mean retinal sensitivity and number of micro-scotomas after a 12-month follow-up.<sup>17</sup> It is also found in literature that superficial retinal hemorrhages occur when the ILM is separated from the surface. These are commonest nasally and believed to represent traction on Muller cells, which surround capillaries within the superficial retinal layers.<sup>18</sup> Chatziralli and coauthors also described that ILM peeling improves macular hole closure rates but can have several consequences on function and structure of retina.<sup>13</sup> Additional tools to help peeling, instrumentation, technique used, and surgeon's experience may all effect the outcome of procedure. Atsuro and colleagues found that the acute

retinal alterations after ILM peeling with the finesse flex loop were visualized at a frequency of less than 10%.<sup>14</sup> In this study comparison between outcomes of ILM peeling with and without using finesse loop showed that there is statistically non-significant difference in occurrence of retinal hemorrhage, retinal tear, retinal detachment and surface irregularities. Out of 30 patients, retinal hemorrhage was reported in only 3 (20%) undergoing retinal peeling with finesse loop, whereas, it is found in 7 (46.7%) patients in which peeling was done without finesse loop ( $p=0.245$ ). Similarly, retinal tear and retinal detachment were not found in any patient undergoing surgery by using finesse loop, but in contrast to it, 20% and 6.7% patients came with retinal tear ( $p=0.224$ ) and retinal detachment ( $p=1.00$ ), respectively, who undergone surgery without using finesse loop. Surface irregularities were seen in 13.3% and 33.3% patients undergoing surgery using and without using finesse loop ( $p=0.39$ ), respectively. ILM peeling with both techniques almost produce same results but ILM peeling with finesse loop relatively gave better results as compared to those in which ILM peeling was done without finesse loop. The most common complications found were retinal hemorrhages and surface irregularities. In one study Inner retinal hemorrhage was observed in more than 37% of patients undergoing ILM peeling with membrane loop. Inner retinal hemorrhage was confirmed by OCT which was localized and small. Subtle superficial retinal hemorrhage was reported in 66 to 75% patients undergoing ILM peeling with forceps or diamond dusted membrane scraper.<sup>19</sup> These self-limited hemorrhages were not found to have any long term effects. Apart from above mentioned complications, paracentral scotomata was observed in another study due to trauma to the nerve fibers during ILM peeling.<sup>20</sup> There are many other complications enlisted in literature as well, like postoperative hyphema and raised intraocular pressure. Subretinal bleedings which causes hyphema can also occur without a direct forceps' injury. Traction from ILM while removing or trauma may cause inner retinal hemorrhage. This tractional force can be avoided by changing angle for ILM peeling with loop.<sup>14</sup> Several limitations for this study should be acknowledged. Our study is limited by small sample size and can be influenced by surgical capability of surgeon performing the surgery.

## CONCLUSION

This study concluded that the prevalence of complications during and after ILM peel with finesse

loop in a macular hole surgery were less than that in ILM peel with ILM forceps alone.

## REFERENCES

1. McCannel CA, Ensminger JL, Diehl NN, Hodge DN. Population-based incidence of macular holes. *Ophthalmol*. 2009; 116(7):1366-1369.
2. Dhama A, Ratna D, Sharma T. Macular hole surgery. *Gems of Ophthalmology: Retina*. 2018:340.
3. Michalewska Z, Michalewski J, Adelman RA, Nawrocki J. Inverted internal limiting membrane flap technique for large macular holes. *Ophthalmol*. 2010; 117(10):2018-2025.
4. Tranos P, Peter N, Nath R, Singh M, Dimitrakos S, Charteris D, et al. Macular hole surgery without prone positioning. *Eye*. 2007; 21(6):802-806.
5. Gross JG. Late reopening and spontaneous closure of previously repaired macular holes. *Am J Ophthalmol*. 2005; 140(3):556-558.
6. D'souza MJ, Chaudhary V, Devenyi R, Kertes PJ, Lam W-C. Re-operation of idiopathic full-thickness macular holes after initial surgery with internal limiting membrane peel. *Br J Ophthalmol*. 2011; 1564-1567.
7. Bainbridge J, Herbert E, Gregor Z. Macular holes: vitreoretinal relationships and surgical approaches. *Eye*. 2008; 22(10):1301-1309.
8. Sano M, Shimoda Y, Hashimoto H, Kishi S. Restored photoreceptor outer segment and visual recovery after macular hole closure. *Am J Ophthalmol*. 2009; 147(2):313-318.e1.
9. Rahimy E, McCannel CA. Impact of internal limiting membrane peeling on macular hole reopening: a systematic review and meta-analysis. *Retina*. 2016; 36(4):679-687.
10. Spiteri Cornish K, Lois N, Scott N, Burr J, Cook J, Bochie C, et al. Vitrectomy with internal limiting membrane (ILM) peeling versus vitrectomy with no peeling for idiopathic full-thickness macular hole (FTMH). *Cochrane Database Syst Rev*. 2013; 2011(9):CD009306.
11. Grinton ME, Sandinha MT, Steel DH. Photoreceptor outer segment on internal limiting membrane after macular hole surgery: implications for pathogenesis. *Case Rep Ophthalmol* 2015;6: 339-344.
12. Khaqan HA, Jameel F. Visual outcomes of macular hole surgery. *J Coll Phys Surg Pak*. 2016; 26(10):839-842.
13. Chatziralli IP, Theodosiadis PG, Steel DH. Internal limiting membrane peeling in macular hole surgery: Why, when, and how? *Retina*. 2018; 38(5):870-882.
14. Uchida A, Srivastava SK, Ehlers JP. Analysis of retinal architectural changes using intraoperative OCT following surgical manipulations with membrane flex loop in the DISCOVER study. *Invest Ophthalmol Vis Sci*. 2017; 58(9): 3440-3444.
15. Steel DHW, Chen Y, Latimer J, White K, Avery PJ. Does internal limiting membrane peeling size matter? *J Vitreoretin Dis*. 2017; 1: 27-33.
16. González-Saldivar G, Chow DR. Update in vitreoretinal instrumentation. *US Ophthalmic Rev*. 2018; 11(2): 98-102.
17. Ripandelli G, Scarinci F, Piaggi P, Guidi G, Pileri M, Cupo G, et al. Macular pucker: to peel or not to peel the internal limiting membrane? A microperimetric response. *Retina*. 2015; 35: 498-507.
18. Steel DH, Dinah C, White K, Avery PJ. The relationship between a dissociated optic nerve fibre layer appearance after macular hole surgery and Muller cell debris on peeled internal

- limiting membrane. *Acta Ophthalmol (Copenh)*. 2017; 95(2):153-157.
19. Steel DH, Dinah C, Habib M, White K. ILM peeling technique influences the degree of a dissociated optic nerve fibre layer appearance after macular hole surgery. *Graefes Arch Clin Exp Ophthalmol*. 2015; 253(5): 691-698.
  20. Haritoglou C, Gass CA, Schaumberger M, Ehrt O, Gandorfer A, Kampik A. Macular changes after peeling of the internal limiting membrane in macular hole surgery. *Am J Ophthalmol*. 2001; 132(3):363-368.