

# Comparison of visual acuity and post-operative inflammation in phacoemulsification and removal of silicone oil with and without injection of Enoxaparin Sodium (40mg/0.04ml)

Hasnain Muhammad Buksh<sup>1</sup>, Hussain Ahmad Khaqan<sup>2</sup>, Usman Imtiaz<sup>1</sup>, Hafiz Ateeq Ur Rehman<sup>3</sup>, Mehreen Afzal<sup>3</sup>, Raheela Naz<sup>3</sup>

<sup>1</sup>VR Fellow Department of Ophthalmology Ameer Ud Din Medical College, PGMI, Lahore General Hospital, Lahore, Pakistan, <sup>2</sup>Associate Professor Department of Ophthalmology Ameer Ud Din Medical College, PGMI, Lahore General Hospital, Lahore-Pakistan, <sup>3</sup>PGR Department of Ophthalmology Ameer Ud Din Medical College, PGMI, Lahore General Hospital, Lahore-Pakistan

**Correspondence to:** Dr. Hasnain Muhammad Buksh, Email: hasnain\_md106@hotmail.com

## ABSTRACT

**Background:** Phacoemulsification and removal of silicone oil (ROSO) is a combined, frequently done procedure in retina theatre. A common problem in this procedure is the post inflammation that affects the recovery of the patients. Thus to counter this post-operative inflammation, the study has used Enoxaparin Sodium (an anti-inflammatory enoxaparin) to counter the post-operative inflammation in phacoemulsification and ROSO.

**Patients and methods:** Prospective interventional study done at Ophthalmology Department, Lahore General Hospital, included 60 patients which were operated and observed for results over a period of 3 months. Total 60 patients were randomly allocated in two groups, Group A and B. Both groups underwent phacoemulsification and ROSO. Group A had Enoxaparin Sodium, admixed in infusion bottles with a dosage of 40mg/0.04ml while Group B was operated without Enoxaparin Sodium. Patients were examined on slit lamp on the 1st day after the surgery then on the 7<sup>th</sup> day and every month for 3 months for post-operative inflammation and visual recovery. The effectiveness of the procedure was defined by the comparison of post-operative inflammation as well as speedy recovery of sight.

**Results:** Total 60 patients were randomly allocated in two groups. Group A had 30 patients, 23 males and 7 females, with mean age of 49.43 years. Group B included 30 patients, 19 males and 11 females, with mean age of 47.73 years. Post-operative BCVA in Group A was above vision 6/60 (Snellen's Chart) in 90% of cases while it improved to vision 6/36 and better in 93% of cases at 7<sup>th</sup> day while 93% of cases crossed recovery of Vision 6/18 by 3<sup>rd</sup> Month. While in Group B, Vision 6/60 was observed in 70% of cases while it improved to vision 6/36 and better in 67% of cases at 7<sup>th</sup> day while 53% of cases crossed recovery of vision 6/18 by 3<sup>rd</sup> Month. Post-operative results for inflammation of Group B showed grade 3 reaction on first day (94%) while it reduced to grade 2 reaction on 7<sup>th</sup> day in 97% of the cases. While Group A was observed with occasional activity in 25 out of 30 cases (84%) on the first day and grade 2 reaction in 5 (16%) cases. 100% cases of Group A showed occasional activity on 7<sup>th</sup> day with better visual recovery.

**Conclusion:** Intraoperative use of Enoxaparin Sodium helped in reducing post-operative inflammation as well as aided in better visual acuity after phacoemulsification and ROSO thus proving to be a viable enoxaparin agent to reduce post-operative reactions in these surgeries.

## Keywords:

Visual acuity, Post-operative inflammation, Enoxaparin sodium, Silicon oil

## INTRODUCTION

Silicone oil in vitreous filling as a tamponade was initially introduced by Cibis and colleagues back in 1962 and since then, silicone oil tamponade has been one of the most common methods to maintain intraocular pressure (IOP) and also retain the retina.<sup>1</sup> However, the use of silicone oil has been troublesome in many cases and the most commonly reported problems are oil emulsification, cataract, corneal degeneration, and glaucoma, etc.<sup>2-4</sup> Since silicone oil

can have problematic effects after some time of vitrectomy, it is always recommended to remove silicone oil after it is no longer required for its tamponade effect.<sup>5</sup> Within the period of 6 to 12 months, silicone oil tamponade can develop into a posterior sub-capsular cataract. However, the pathogenesis for such a problematic effect of silicone oil tamponade has not been clarified extensively. Currently, to prevent the post-operative cataract effect of oil tamponade, no definite measure has been recommended. However, one of commonly used and feasible method is the removal of silicone oil (ROSO) as soon as the retina stabilizes.<sup>6</sup> Unfortunately, in many cases, silicone oil may not be removed for a while and consequently develop a posterior cataract. Thus, oil and cataract extraction surgery is the only method to restore

**Conflict of interest:** The authors declared no conflict of interest exists.

**Citation:** Buksh HM, Khaqan HA, Imtiaz U, Rehman HAU, Afzal M, Naz R. Comparison of visual acuity and post-operative inflammation in phacoemulsification and removal of silicone oil with and without injection Enoxaparin Sodium (40mg/0.04ml). J Fatima Jinnah Med Univ. 2020; 14(4): 185-190.

**DOI:** <https://doi.org/10.37018/xmpi6453>

the vision of the patient.<sup>6</sup> Phacoemulsification combined with a ROSO surgery is the most effective and convenient method to restore eyesight and is a less invasive method.<sup>7-8</sup> However, inflammation after the operation remains trouble for eye surgeons. Here, the use of blood thinners or enoxaparin such as Enoxaparin Sodium presents a solution to the inflammation problem. Enoxaparin Sodium has never been used in the previous researches as an agent of anti-inflammation directly used in the infusion bottle in the surgical procedure. The reason to use Enoxaparin Sodium is that after Phacoemulsification and ROSO, blood cells in the anterior chamber can accumulate to cause inflammation after the surgery and also limit the revival of eyesight immediately after the surgery, Enoxaparin Sodium as appropriate heparin has been used in this study to prevent inflammation post-operatively. Injecting Enoxaparin Sodium does not allow the binding of pigment cells thus acting as an excellent anti-inflammatory.

#### PATIENTS AND METHODS

A total of 60 patients (42 males and 18 females) were included in this study with each patient having one eye cataract development and admitted for ROSO. All patients underwent phacoemulsification as well as removal of silicon oil (ROSO) in the Ophthalmology Department of Lahore General Hospital, Lahore. The patients were admitted for surgery from 15<sup>th</sup> February 2019 till 15<sup>th</sup> February 2020. All patients were screened from the Retinal Clinic, Outpatient Department, who went a previous pars plana vitrectomy (PPV), and 5000-centistoke Silicone oil was used as a tamponade 12 to 14 months back. All patients underwent a complete pre-operative examination including vision with Snellen's chart, intraocular pressure (IOP) (mm Hg), diagnosis for cataract, fundus examination, and a 360° barrier laser. Out of 60 patients, only 3 patients had laser before surgery. Patients with only 1 previous retinal surgery history having silicon oil as a tamponade and cataract development were included in the study. Patients with corneal opacities, high IOP, neovascularization on iris and sub-silicon oil retinal detachments were excluded. All surgeries were performed by a single surgeon. The patients were randomly divided into 2 Groups by using a random sampling method. Group A had 30 patients that went through phacoemulsification and silicone oil removal but Group A was provided with Enoxaparin Sodium injected in 1000 ml ringer lactate in two separate bottles (two injections were used per surgery). Group B also

had 30 patients randomly selected and went through phacoemulsification as well as ROSO without injection Enoxaparin Sodium being used as an anti-inflammatory. Phacoemulsification was performed as a first step and two way irrigation aspiration cannula was attached with an infusion bottle of 1000ml Ringer Lactate in which Enoxaparin Sodium 40mg/0.04ml was added. The injection was dispensed in the same dose and whole dosage was added in 1000 ml ringer lactate. The dose was selected after discussion with a physician member of ethical review board as it does not carry any side effect in fact proved to be a good anti-inflammatory by avoiding aggregation of inflammatory cells. After performing phacoemulsification, removing cortical matter and putting in the Intraocular Lens (IOL), limbal sutures were placed and three 23 gauge ports were placed at pars plana. One port was attached with a fluid to maintain the eye volume during ROSO part in which injection Enoxaparin Sodium was added Two ports used for the removal of silicon oil, once all the silicon oil is removed cavity is checked and fluid (with admixed Enoxaparin Sodium) is allowed to wash through for some time. During this time status of retina is checked and laser if found inadequate was augmented. At the end ports were removed and sutured to avoid post-operative hypotony. The amount of Enoxaparin Sodium injected in infusion bottles was limited to 40mg/0.04ml so to act as low molecular weight heparin mixed infusion bottles. Patients were examined on slit lamp before the surgery and 1<sup>st</sup> day after the surgery then on the 7<sup>th</sup> day and every month for three months by measuring their Snellen's chart vision. The inflammation was also observed in these periods while grading the reactivity (grade 3 to occasional activity). All patients involved in the research were included with proper informed consent as well as the doctrines of ethics were followed throughout the research as set out by the declaration of Helsinki. SPSS statistical analysis software (version 13.0) was used for statistical analysis. The use of a t-test with a p-value of <0.05 was taken as significant.

#### RESULTS

A total of 60 patients were included in the study and randomly divided in 2 Groups. Group A had 30 patients including 23 males and 7 females. Age of Group A patients ranged between 27 to 69 years (mean age 49.43 years+12.87). Group B included 30 patients including 19 males and 11 females with age range between 24 years to 63 years (mean 47.73 years +11.68). Group A in this study was treated by injecting Enoxaparin Sodium

Table 1. Postoperative Snellen's chart BCVA value at day 1, day 7 and day 30

Post-op Snellen's vision	Groups		Total
	With Injection of Enoxaparin Sodium	Without Injection of Enoxaparin Sodium	
<b>Day 1</b>			
Vision 6/12	3	0	3
Vision 6/18	6	0	6
Vision 6/24	9	1	10
Vision 6/36	6	11	17
Vision 6/60	3	9	12
CF	3	7	10
HM	0	2	2
<b>Day 7</b>			
Vision 6/18	9	3	12
Vision 6/24	11	8	19
Vision 6/36	8	9	17
Vision 6/60	2	6	8
CF	0	3	3
HM	0	1	1
<b>Day 30</b>			
Vision 6/6	2	0	2
Vision 6/9	6	0	6
Vision 6/12	3	0	3
Vision 6/18	17	16	33
Vision 6/24	0	4	4
Vision 6/36	2	3	5
Vision 6/60	0	5	5
HM	0	2	2

(40mg/0.04ml) in their infusion bottle during the phacoemulsification and ROSO surgery. While, Group B was not given any dosage of Enoxaparin Sodium or any other anti-inflammatory during the whole procedure. Figure 1 describe the pre-operative Best Corrected Visual Acuity (BCVA) measured via Snellen's chart. Both Groups included nearly similar cases of BCVA. The post-operative results for the period of day 1, day 7 and 3<sup>rd</sup> month are described in the Table 1.

From the above tables, it can be clearly observed that BCVA recovery was significant in the case of Group A while in the Group B, the recovery was not speedy and significant enough as compared to Group A. Taking Vision 6/60 as the cut off value, the Group A on 1<sup>st</sup> Day had 27 out of 30 (90%) patients above the cut off value 21 out of 30 (70%) cases were above the cut off value in Group B.

Day 7 also included better results in the Group A where 28 out of 30 (93%) patients had BCVA recovery of Vision 6/36 and over while group B only 20 out of 30 (67%) patients with vision 6/36 and better BCVA. After 3<sup>rd</sup> Month, the BCVA values significantly improved in the Group A and B alike but BCVA values in Group A were significantly better than Group B. 28 out of 30 (93%) patients had vision 6/18 and better in Group A while 16 out of 30 (53%) could achieve 6/18 BCVA value after 3 months in Group B.

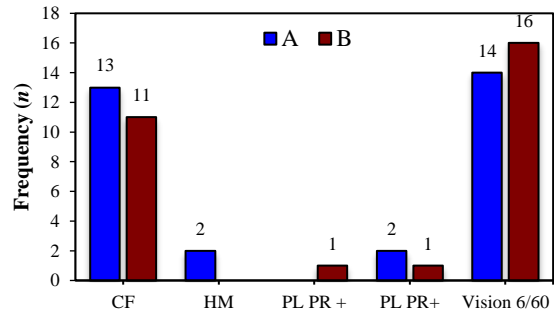


Figure 1. Pre-operative Snellen's vision

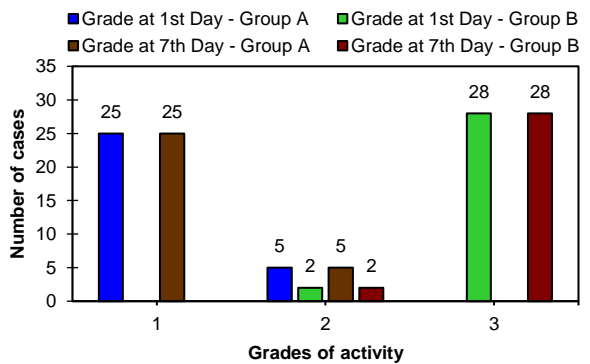


Figure 2. Inflammation at day 1 and day 7

All the Relations between the mean values of the post-operative results were found significant at 2-tailed significance value of  $p < 0.05$ . The variation of mean difference in the t-test clarify that the BCVA improved over the time of 3 months for all patients. However, the individual analysis in the upper section shows better results in Group A. A Pearson Correlation test was also performed and included in the list of tables for further proof of statistical significance.

Group A was dosed with Enoxaparin Sodium and at the very first day, 25 out of 30 patients only had Occasional Activity while in the Group B, 28 of 30 patients showed a 3<sup>rd</sup> grade inflammatory reaction after phacoemulsification and ROSO. Thus, to control and reduce the inflammation in the Group B, further steroid medication was prescribed.

Similarly, inflammation was also graded at the 7<sup>th</sup> day where the group A showed only occasional activity in the anterior chamber for all 30 cases while the group B had recovered but still showed Grade 2 activity in the anterior chamber with 1 case still showing grade 3 inflammation.

Further statistical analysis (t-test) were performed and the results showed that all the relations between the mean values of the post-operative results were found

Table 1. Independent sample t-test for BCVA

t-test for Equality of Means	F	t	df	Sig. (2-tailed)
Pre-Op Snellen's Vision	0.028	0.924	58	0.359
Post-Op Snellen's Vision - Day 1	3.491	-5.074	58	0.000
Post-Op Snellen's Vision - Day 7	1.936	-3.252	58	0.002
Post-Op Snellen's Vision - Day 30	2.329	-4.798	58	0.000

Tables: Pearson correlation – BCVA

Pre-Op Snellen's Vision	Pre-Op Snellen's Vision	Post-Op Snellen's Vision - Day 1	Post-Op Snellen's Vision - Day 7	Post-Op Snellen's Vision - Day 30
Pearson Correlation	1	.427**	.293*	.321*
Sig. (2-tailed)		.001	.023	.012
N	60	60	60	60

\*\* . Correlation is significant at the 0.01 level (2-tailed).

\*. Correlation is significant at the 0.05 level (2-tailed).

Pearson Correlation – Inflammation in the anterior chamber

	Anterior Chamber Activity grade - Day 1	Anterior Chamber Activity grade - Day 7
<b>Anterior Chamber Activity Grade - Day 1</b>		
Pearson Correlation	1	.916**
Sig. (2-tailed)		.000
N	60	60
<b>Anterior Chamber Activity Grade - Day 7</b>		
Pearson Correlation	.916**	1
Sig. (2-tailed)	.000	
N	60	60

\*\* . Correlation is significant at the 0.01 level (2-tailed).

significant at 2-tailed significance value of  $p < 0.05$ . The variation of mean difference in the t-test clarify that the inflammation improved over the time of 7 days for all patients. However, the individual analysis in the upper section shows better results in Group A. A Pearson Correlation test was also performed and included in the list of tables for further proof of statistical significance.

There was no severe complication observed in both the groups. The follow-up period of the patients was up to 3 months. 1<sup>st</sup> day examination showed grade 3 inflammation in all patients of group B which was significantly removed after steroid dosages. Vision recovered for all patients in the study while Group A (injected with Enoxaparin Sodium 40mg/0.04ml) had a **better recovery rate for BCVA measured via Snellen's chart**. As can be seen in the Tables 1 and 2, the BCVA improvement in Group A was much better while in Group B, BCVA improvement was minimal as compared to the Enoxaparin Sodium group.

## DISCUSSION

The method of combined phacoemulsification and ROSO has been studied and reported as the most convenient procedure for treating cataract development from previous vitreous surgeries. The use of silicone oil in the vitreoretinal surgery was introduced in 1962 and even though 50+ years have passed, it still remains as the best accepted and widely used vitreous substitute in the retinal surgical department.<sup>1,9</sup> The advantages of the

silicone oil used as a tamponade have been significant but there is a great disadvantage of cataract development observed in almost 90% of cases.<sup>10</sup> The reasons for inflammation and cataract development have been studied by Mackiewicz and coworkers.<sup>11</sup> They reported that impurities and instability of the tamponade agent, its toxicity, and immunogenicity are the observed causes. The complication followed right after silicone removal have been troubling the intraocular surgeries.<sup>12</sup> Blood-retinal retinal alterations can cause severe inflammation after phacoemulsification and ROSO.<sup>13</sup> Remedies for post-operation **inflammation in the patient's eye is less researched area**. The commonly used method to counter the inflammation of the anterior chamber is to use post-operative steroids. However, the use of post-operative steroids is a lengthy process and can take up to 2 weeks to have a significant soothing effect. Non-Steroid anti-inflammatory drugs thus are the potential solution that can be used pre-operatively to exclude the complication of inflammation after cataract surgeries. Lim and coauthors summarized 54 studies that developed Non-Steroid Anti-Inflammatory Drugs (NSAID) for treating post-operative inflammation and macular oedema.<sup>14</sup> The review used multiple studies from American, European, and South Asian journals regarding the use of NSAIDs. Several NSAIDs were identified to be used in this regard including diclofenac, indomethacin, ketorolac, nepafenac, pranopfen and flurbiprofen.<sup>15-20</sup>

Authors concluded that all studies showed weak results, as well as the reporting of results, was biased, affected, and insufficient. The review also concluded that none of the study produced significant results as the post-operation follow up was up to 12 months. Authors also observed that the current estimates from multiple NSAID-based studies exaggerated as well as the unclear view of the effects of NSAIDs on visual acuity was a hindering factor. Evidence to support post-operative vision improvement was also insufficient. Thus, declaring that the use of NSAID for controlling inflammation and cataract development in intraocular surgeries has uncertain results.<sup>14</sup> Present study studied Enoxaparin Sodium as a viable solution to stop the inflammatory cells clumping and pigmentation in the eye. Enoxaparin Sodium not only as Enoxaparin has the benefit of acting as an anti-inflammatory agent but from our research, it showed that due to this **anti-inflammation property, the patient's vision recovery (BCVA) was much better after a day.** Compared to Group B (Without Enoxaparin Sodium) where in some cases, the post-operative BCVA worsened. While in Group A (With Enoxaparin Sodium), vision in all cases improved significantly right after 24 hours without any complication and inflammation. Thus, it shows that Enoxaparin Sodium is not just suitable for eliminating the inflammation problem in phacoemulsification and ROSO, but it also acts as an agent to recover the patient's vision within 24 hours of the surgery, which as compared to the lengthy time of traditional method is significantly faster and better. The Enoxaparin Sodium group had no post-operative complications while the other had severe cases as well.

The reason for such better recovery rates in Group A is because of the use of Enoxaparin Sodium as an anti-inflammatory during the procedure. Nearly in all cases of Group A, there was significant BCVA improvement recorded after the surgery. While Group B had a majority of cases where post-operative BCVA didn't improve while in some cases, it got worst and needed medical attention due to inflammation. Thus, Enoxaparin Sodium as heparin this kind of surgery proves to be a suitable and efficient anti-inflammatory agent with the immediate benefit of BCVA improvement as a bonus.

The study had no limitations in the research process except the fact that the number of patients was limited to 60. But all the recruited patients were treated and operated by the same surgeon group and post-operative follow-ups were also done by the same team.

## CONCLUSION

Enoxaparin Sodium was used as anti-inflammatory agent added to infusion bottle in phacoemulsification and ROSO procedures. The study concluded beneficial and potential use of Enoxaparin Sodium as an anti-inflammatory agent where it not only reduced the post-operative inflammation and reaction but also decreased the visual recovery period of patients. Thus, Enoxaparin Sodium presents itself as a significant anti-inflammatory for cataract surgeries such as phacoemulsification and silicone oil removal resulting from previous retinal surgeries.

## REFERENCES

1. Cibis PA, Becker B, Okun E, Canaan S. The use of liquid silicone in retinal detachment surgery. *Arch Ophthalmol.* 1962; 68:590-9. doi: 10.1001/archophth.1962.00960030594005
2. Grewal DS, Singh Grewal SP, Basti S. Incomplete femtosecond laser-assisted capsulotomy and lens fragmentation due to emulsified silicone oil in the anterior chamber. *J Cataract Refract Surg.* 2014; 40(12):2143-7. doi: 10.1016/j.jcrs.2014.09.022
3. Singh D, Chandra A, Sihota R, Kumar S, Gupta V. Long-term success of mitomycin-augmented trabeculectomy for glaucoma after vitreoretinal surgery with silicone oil insertion: a prospective case series. *Retina.* 2014; 34(1):123-8. doi: 10.1097/IAE.0b013e31828fcb2e
4. Al-Wadani SF, Abouammoh MA, Abu El-Asrar AM. Visual and anatomical outcomes after silicone oil removal in patients with complex retinal detachment. *Int Ophthalmol.* 2014; 34(3):549-56. doi: 10.1007/s10792-013-9857-9
5. Grzybowski A, Pieczynski J, Ascaso FJ. Neuronal complications of intravitreal silicone oil: an updated review. *Acta Ophthalmol.* 2014; 92(3):201-4. doi: 10.1111/aos.12212
6. Xu W, Cheng W, Zhuang H, Guo J, Xu G. Safety and efficacy of transpupillary silicone oil removal in combination with micro-incision phacoemulsification cataract surgery: comparison with 23-gauge approach. *BMC Ophthalmol.* 2018; 18(1):200. doi: 10.1186/s12886-018-0878-z
7. Clark C, Habib MS, Steel DH. Combined phacoemulsification and transpupillary removal of heavy silicone oil. *J Cataract Refract Surg.* 2008; 34(10):1640-3. doi: 10.1016/j.jcrs.2008.05.054
8. El Baha SM, Abouhusein MA, Hemeida TS. Sutureless phacoemulsification with transpupillary removal of silicone oil and intracapsular intraocular lens implantation using illuminated 23-gauge infusion system. *Retina.* 2011; 31(2):408-12. doi: 10.1097/IAE.0b013e318200921b
9. Semeraro F, Russo A, Morescalchi F, Gambicorti E, Vezzoli S, Parmeggiani F, et al. Comparative assessment of intraocular inflammation following standard or heavy silicone oil tamponade: a prospective study. *Acta Ophthalmol.* 2019; 97(1):e97-e102. doi: 10.1111/aos.13830.
10. Sinha S. Minimally invasive vitreous surgery: 20 gauge to 27 gauge. 1<sup>st</sup> ed. Vol. 2. New Delhi: Jaypee Brothers Medical Publishers (P) Ltd; 2013.
11. Mackiewicz J, Mühling B, Hiebl W, Meinert H, Maaijwee K, Kociok N, et al. In vivo retinal tolerance of various heavy silicone oils. *Invest Ophthalmol Vis Sci.* 2007; 48(4):1873-83. doi: 10.1167/iovs.06-0941

12. Assi A, Woodruff S, Gotzaridis E, Bunce C, Sullivan P. Combined phacoemulsification and transpupillary drainage of silicone oil: results and complications. *Br J Ophthalmol*. 2001; 85(8):942-5. doi: 10.1136/bjo.85.8.942
13. Tranos PG, Wickremasinghe SS, Stangos NT, Topouzis F, Tsinopoulos I, Pavesio CE. Macular edema. *Surv Ophthalmol*. 2004;49(5):470-90.
14. Lim BX, Lim CH, Lim DK, Evans JR, Bunce C, Wormald R. Prophylactic non-steroidal anti-inflammatory drugs for the prevention of macular oedema after cataract surgery. *Cochrane Database Syst Rev*. 2016;11(11):CD006683. doi: 10.1002/14651858.CD006683.pub3.
15. Asano S, Miyake K, Ota I, Sugita G, Kimura W, Sakka Y, et al. Reducing angiographic cystoid macular edema and blood-aqueous barrier disruption after small-incision phacoemulsification and foldable intraocular lens implantation: multicenter prospective randomized comparison of topical diclofenac 0.1% and betamethasone 0.1%. *J Cataract Refract Surg*. 2008;34(1):57-63. doi: 10.1016/j.jcrs.2007.08.030
16. Urnerbloch U. Should indomethacin be used topically to prevent aphakic cystoid macular edema. *Inklinische Monatsblätter Fur Augenheilkunde* 1983. 182(5): 495-496.
17. Wittpenn JR, Silverstein S, Heier J, Kenyon KR, Hunkeler JD, Earl M. Acular LS for Cystoid Macular Edema (ACME) Study Group. A randomized, masked comparison of topical ketorolac 0.4% plus steroid vs steroid alone in low-risk cataract surgery patients. *Am J Ophthalmol*. 2008; 146(4):554-560. doi: 10.1016/j.ajo.2008.04.036
18. Almeida DR, Khan Z, Xing L, Bakar SN, Rahim K, Urton T, et al. Prophylactic nepafenac and ketorolac versus placebo in preventing postoperative macular edema after uneventful phacoemulsification. *J Cataract Refract Surg*. 2012; 38(9):1537-43. doi: 10.1016/j.jcrs.2012.04.034
19. Zhang HY, Zhu SQ. Clinical study of Pranoprofen eye drops on prophylaxis of cystoids macular edema after cataract surgery. *International Journal of Ophthalmology*. 2008; 8(7):1370-2.
20. Solomon LD. Efficacy of topical flurbiprofen and indomethacin in preventing pseudophakic cystoid macular edema. Flurbiprofen-CME Study Group I. *J Cataract Refract Surg*. 1995; 21(1):73-81. doi: 10.1016/s0886-3350(13)80484-1