

Diagnostic accuracy of Non-ECG Gated Chest CT (NEGCT) for cardiac chambers' dimensions in comparison with echocardiography

Mahnor Hafeez¹, Amjad Sattar²

¹Senior Instructor Dow Institute of Radiology, Dow University of Health Sciences, Karachi-Pakistan, ²Associate Professor, Dow Institute of Radiology, Dow University of Health Sciences, Karachi-Pakistan

Correspondence to: Dr. Mahnor Hafeez, Email: mahnor.hafeez@duhs.edu.pk

ABSTRACT

Objective: To analyze the accuracy of Non-ECG Gated Chest CT (NEGCT) for cardiac chambers' dimensions, keeping Echocardiography as the gold standard.

Methods: After IRB approval, all patients that underwent concurrent contrast chest CT/CTPA and transthoracic 2D echocardiography exam at our institute within 1 month interval comprised the study population. Data was archived from HMIS PACS Database. The sizes of right ventricle (RV), left ventricle (LV) and left atrium (LA) was recorded in short axis at axial CT sections and at echocardiography. RV and LV-transverse diameter was measured at basal third of the heart, from the inner to inner myocardium perpendicular to the inter-ventricular septum and LA-max. Anterior-posterior dimension was measured at the level of the aortic root.

Results: Total 213 subjects were studied, with average age of 52.1±15.8 years. The CT-Echocardiography measurement concordance rates were significantly high for LA, LV and RV measuring 93.8%, 96.7% and 69.01% respectively. Using CT threshold for LA, LV, RV enlargement > or equal to 45, 55, 35mm, the AUC via ROC curve analysis was estimated to be 0.912, 0.992, 0.650 respectively. The sensitivity, specificity, positive predictive value (PPV), negative predictive value (NPV) and diagnostic accuracy of NEGCT was found to be 66.67%, 95.10%, 37.5%, 98.5% and 93.90% for LA; 100%, 96.67%, 30.0%, 100%, 96.7% for LV and 33.33%, 74.86%, 17.86% 87.26% and 69.01% for RV respectively.

Conclusion: Overall, the accuracy of chamber dimensions at NEGCT was excellent with high CT-Echocardiography concordance, making it an alternative modality for examining chamber sizes, in the absence of cardiac MRI. Through it, a radiologist can also add more value to CT reporting.

Keywords:

Echocardiography, NEGCT, Dimensional Measurement

INTRODUCTION

Transthoracic echocardiography (TTE) is a noninvasive first-line technique for cardiac function evaluation including LVH, EF and heart size measurements. Morphological assessment of heart has understudied area among Radiologists at CT scans. Reporting cardiomegaly on supine Chest Radiographs and CT scans has been a matter of debate because of pseudo-enlargement due to gravitational changes; though there is enough evidence from one cited article in 2012¹ that the cardiothoracic ratio at routine CT scans was highly correlated with that at CXR. Cardiac MRI is considered the reference standard for the evaluation of cardiac size and function². However, it is less performed. ECG-gated Contrast Chest CT, also known as 'Cardiac CT' involves monitoring of heart beat during acquisition. It

minimizes pulsation artifacts from a beating heart and is specifically indicated for coronary angiography assessment³. Routine Contrast Chest CT and CTPA (done without gating) can also create fine images of the heart, without blurring artifacts because new scanners have high spatial resolution because of the thin section protocol usage and z axis coverage.

In the last decade, Non-ECG gated Chest CT scan (NEGCT) is of specific interest for studying heart morphology, thrombus, septal defects, valves, coronary calcification⁴. In no way, CT scan surpasses echocardiography, which is a real-time imaging, but detection of incidental cardiac chamber enlargement at an early stage of cardiac disease, can help in early referral and management⁵. It's one of the important ways of assessing cardiac disease. It is well-documented phenomena that enlarged cardiac chambers are predictors of morbidity and mortality of variety of cardiovascular processes⁶. Causes of left atrial (LA) and left ventricle (LV) enlargement include mitral and aortic valve disease, ischemic heart disease and causes of

Conflict of Interest: The authors declared no conflict of interest exists.

Citation: Hafeez M, Sattar A. diagnostic accuracy of Non-ECG Gated Chest CT (NEGCT) for cardiac chambers' dimensions in comparison with echocardiography. J Fatima Jinnah Med Univ. 2022; 16(2):53-57.

DOI: <https://doi.org/10.37018/MHAS.0901>

Right Ventricle (RV) enlargement include tricuspid or pulmonary regurgitation, pulmonary hypertension, cardiomyopathy, and CHD, including left to right shunts⁷.

Few articles have mentioned cut off threshold values for chamber sizes at CT. Chaturvedi *et al.*⁵ documented LV short axis diameter of more than 54.3 mm had a sensitivity of 0.62 and specificity of 0.98. Proposed normal RV transverse diameter has cut-off <45 mm⁸ at CT. Huckleberry J *et al.* studied the accuracy of CT for left ventricular and left atrial enlargement in pilot (n=93) and validation group (n=201) at CT angiography, keeping Echo as gold standard; cutoff values of 55 and 45 mm were chosen for LVE and LAE, respectively. The average sensitivity and specificity for LAE were up to 71% and 94% resp. that for LVE were 41% and 99%, respectively⁸. Assessment of cardiac chambers by CT scan is a less studied area in our clinical practice because of the scarcity of literature. To the best of authors' knowledge, there has been no such study conducted before in Pakistan; it provides us a strong rationale to conduct this study. The objective of our study is to analyze the accuracy of NEGCT for cardiac chambers' dimensions, keeping Echocardiography as the gold standard.

SUBJECTS AND METHODS

All patients that underwent concurrent contrast chest CT/CTPA and Echocardiography exam at our tertiary care institute within 1 month interval comprised the study population. A Data set of one year from January 2020 to December 2020, comprising ID list of transthoracic 2D Echocardiography and CT examinations was archived via Excel 'MATCH' formula from 'HMIS' PACS Database at Dow Institute of Radiology (DUHS), Karachi, Pakistan. It was a descriptive cross-sectional study. The IRB exemption was sought in this study [IRB-1974/DUHS/Approval/2021/]. There was no direct contact with patients. Data with incomplete information and studies with motion artifacts were omitted. Non-contrast CT chest exams were not the study component because of non-mural enhancement in plain studies. All CT examinations were done with single breath hold without ECG gating, 1mm slice thickness and 120 KVP acquisitions at SIEMENS 16-slice, GE 128-slice scanner. Images were analyzed at DICOM viewer. Echocardiograms were done by certified professional at Vivid S 5GE and Concurrent Echocardiography report measurements of right ventricle (RV), left ventricle (LV), right atrium (RA),

left atrium (LA), aortic root size and width of inter-ventricular septum were noted.

Right atrial chamber size was not the mandate of study as this dimension was not routinely measured during Echocardiography at our institute. Regarding the left ventricle, diastolic dimension was recorded. The defined technique for triple chamber measurement (in mm) at CT axial sections was RV-largest transverse diameter was measured at the basal third of the heart, from the inner to inner myocardium perpendicular to the RV long axis; LA-greatest anterior-posterior (AP) dimension at the level of the aortic root; LV-transverse diameter was measured at the mid ventricular level, perpendicular to the inter-ventricular septum. The arbitrary cutoff threshold values for the heart chamber sizes at CT according to recent international literature were RV -45 mm, for LA -45 mm, for LV -55mm. Defined Echocardiography cutoff threshold chamber sizes at our institute were RV <25 mm, LA <40 mm, LV <55 mm. Cardiac chamber size was the outcome variable (Figure 1).

Data was categorized according to gender, with and without chamber enlargement. Chi-square test was used to assess the association of gender with specific chamber enlargement. Analysis was done at SPSS (version 17). STARD 2015 [Standard for Reporting Guideline for Diagnostic Accuracy Studies] was applied. Accuracy, sensitivity, specificity, positive predictive value (PPV), negative predictive value (NPV) and Likelihood Ratios of CT was assessed for estimating chamber sizes. Receiver operating characteristic (ROC) and area under the curve (AUC) was constructed from true and false positive rates. Inter-observer agreement was assessed for chamber sizes at CT and echocardiography via Cohen's kappa statistics. The level of significance (α) was 0.05 in the study.

RESULTS

Total 213 subjects were included in the study comprising of 178 contrast chest CT and 35 CTPA examinations; mean age of 52.1±15.8 years, range 15–88 years. At Echocardiography, enlarged chambers were found in 18 males and 10 females, out of 71 males and 142 females. The prevalence of chamber enlargement in men was 25.3% and in women was 7%. Chi-square test showed significant association of male gender with chamber enlargement (p value<0.001).

The mean Cohen's kappa value for CT-Echocardiography measurements of LA was 0.45, LV was 0.45 (moderate agreement) and RV was 0.06 (slight agreement). The CT-Echocardiography concordance

rates were significantly high for high for measured chambers with low discordant rates (Table 1). Pearson correlation showed a small positive correlation for IVS CT-Echocardiography measurements with r value of 0.27 and small positive correlation for CT-Echocardiography dimensions of ascending aorta with r value of 0.29.

At CT, 38.5% (82/213) subjects were found to have enlarged chambers; right ventricular enlargement (RVE) in 56, left atrium enlargement (LAE) in 16, left ventricular enlargement (LVE) in 10 cases. Maximum no. of false positive cases were seen for RV enlargement. At Echocardiography, statistics showed RVE in 30, LAE in 9, LVE in 3 subjects. The accuracy measurements for cardiac chambers are presented in Table no. 2.

The positive likelihood ratios for chamber enlargement depict mild and moderate probability for LAE and LVE in our population. Using an arbitrary threshold, the ROC curve for chamber measurements

was deviated toward the left side beyond the diagnostic reference line with AUC was estimated to be 0.912, 0.992, 0.650 for LA, LV and RV respectively (Figure 2).

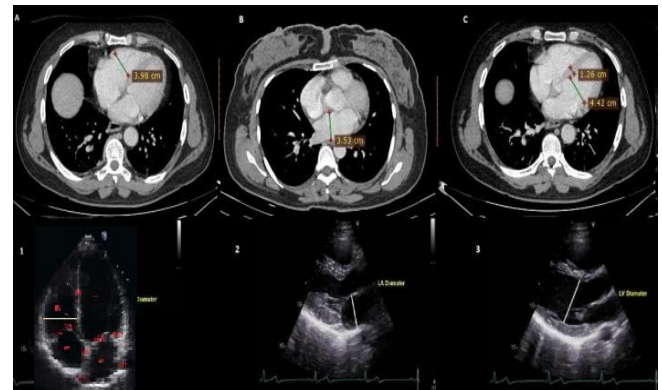


Figure 1: Pictorial representation of CT (Fig. A, B, C) and Echocardiography (Fig. 1, 2, 3) measurements for RA, LA and LV chambers.

Table 1: Measures of diagnostic accuracy for chamber enlargement at NEGCT examinations

Chamber Dimensions CT	CT-Echocardiography Agreement for chamber Measurement		CT-Echocardiography Agreement For chamber Measurement
Left Atrium (LA)			
Yes = 16	6 (TP)	10 (FP)	**K value 0.45 *p value <0.001
No = 197	3 (FN)	194 (TN)	
Total n= 213			
Left Ventricle (LV)	Yes	No	
Yes = 10	3 (TP)	7 (FP)	**K value 0.45 *p value <0.001
No = 203	0 (FN)	203 (TN)	
Total n= 213			
Right Ventricle (RV)	Yes	No	
Yes = 157	10 (TP)	46 (FP)	**K value 0.06 *p value <0.001
No = 56	20 (FN)	137 (TN)	
Total n= 213			

Yes implies Enlarged diameter, No implies Normal diameter

** Cohen's Kappa statistics

*p value is statistically significant at <0.05 levels

Table 2: Diagnostic Performance of NEGCT for detection of chamber measurements, compared with echocardiography

CT Threshold (mm)	No. of Subjects (n)	Sensitivity (%)	Specificity (%)	PPV ^a (%)	NPV ^b (%)	Diagnostic Accuracy (%)	*AUC	Likelihood Ratio	
								Positive	Negative
LA Enlargement > or equal to 45	Total (213)	66.67 [CI 29.9-92.5]	95.10 [CI 91.3- 97.6]	37.5	98.5	93.90 [CI 91.3- 97.6]	0.912	13.6	0.35
	Female (142)	71.43 [CI 29.0- 96.3]	95.56 [CI 90.6 -98.3]	45.45	98.47	94.37 [CI 89.2- 97.5]		16.07	0.30
	Men (71)	50.00 [CI 1.26- 98.7]	94.20 [CI 85.8- 98.4]	20.00	98.48	92.9 [CI 84.3- 97.7]		8.62	0.53
LV Enlargement > or equal to 55	Total (213)	100 [CI 29.2 -100]	96.67 [CI 93.25- 98.6]	30.0	100	96.7 [CI 93.3- 98.7]	0.991	30.0	0.00
	Female (142)	-	99.30 [CI 96.1-99.9]	0.00	100	-		-	-
	Men (71)	100.00 [CI 29.24- 100]	91.18 [CI 81.8- 96.7]	33.33	100	91.55 [CI 82.5-96.8]		11.33	0.00
RV Enlargement > or equal to 35	Total (213)	33.33 [CI 17.29 -52.8]	74.86 [CI 67.9- 80.97]	17.86	87.26	69.01 [CI 62.3- 75.1]	0.650	1.33	0.89
	Female (142)	29.41 [CI 31-55.96]	76.80 [CI 68.41-83.8]	14.71	88.89	71.13 [CI 62.9- 78.4]		1.27	0.92
	Men (71)	38.46 [CI 13.9- 68.42]	70.69 [CI 57.3 -81.9]	22.73	83.67	64.79 [CI 52.5- 75.8]		1.31	0.87

*CI= Confidence Interval
negative

*AUC= Area under the Curve

^b Negative predictive value: probability that the disease is not present when the test is

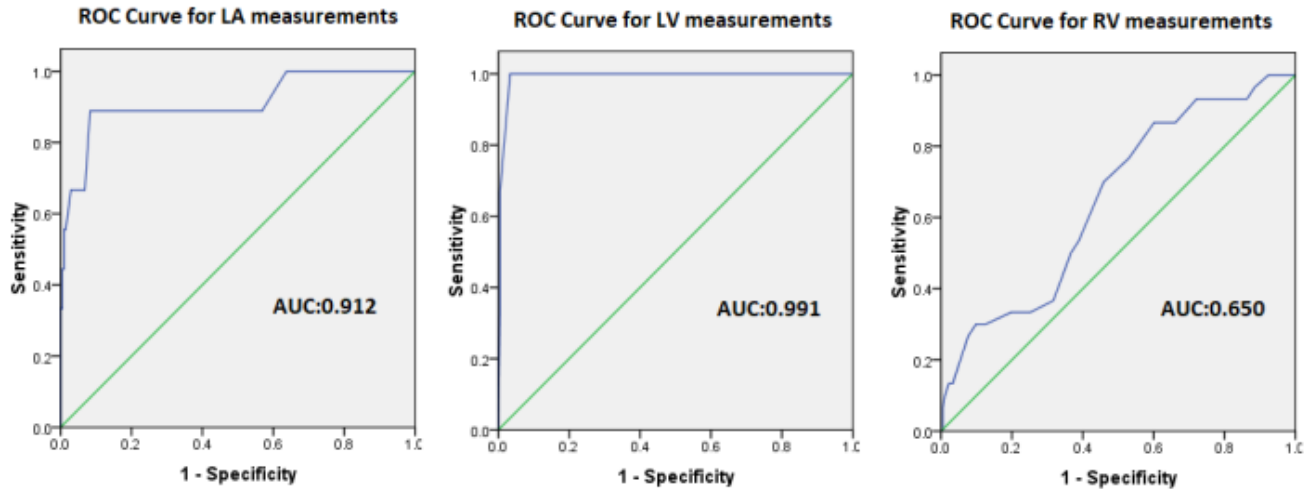


Figure 2: Receiver operating characteristics (ROC) curve for accuracy of cardiac chambers at NEGCT.

DISCUSSION

The cardiovascular findings at NEGCT among the General Radiologists are frequently under reported⁸. However, on the scrutiny of international literature, NEGCT has gained attention for evaluation of cardiovascular problems and it makes sense because CT Chest has widespread availability; it's also the first line investigation for chronic dyspnea of pulmonary etiology¹⁰ and for diagnosing pulmonary embolic disease (PED). On the other hand, ECG gated CT; the gold standard modality for acute chest pain; requires specific software installation and high level of expertise and training. An accurate assessment of cardiac chambers on Chest CT is needed for timely referral and appropriate Patient management.

The aim of this study was to assess the accuracy of NEGCT for cardiac chamber measurements cut off chamber measurements selected in the study were slightly different for CT and Echocardiography, because of differences in the technique of the modalities. This study showed that average diagnostic accuracy, sensitivity, specificity for left-sided chambers was 83.3%, 95.9%, and 95.3%, which was analogous to the study results of Huckerberry *et al.* in which sensitivity and specificity for LAE was up to 71% and 94% respectively that for LVE was 41% and 99%, respectively⁷. This study has used the threshold value of LVE of 56 mm, a sensitivity of 78%, specificity of 100%, using echocardiography as the standard of reference¹¹, comparable to our study. In one recent research¹², the prevalence of RVE, LAE, LVE in men was 11%, 40% and 24% and in women, it was 15%,

27% and 12% respectively, while in this study, prevalence for overall chamber enlargement in men and women was 25.3% and 7% respectively.

In 2018, Eifer DA *et al.*¹² reported high specificity and sensitivity of NEGCT on axial chest CT images with cardiac MRI as the reference standard. They reported high chest CT-cardiac MRI inter-observer agreement being >0.7; in another study, Gürdoğan M. *et al.*¹³ determined high concordance rates for CT-Echocardiography measurements with Intra-class correlation coefficient (ICC) values >0.8; analogous to our study, which demonstrated more than 90% CT-Echocardiography concordance for left-sided chambers.

In the past decade, there has been a dramatic surge to observe 'CT cardiac chamber size' accuracy using quantitative techniques including 1D, 2D, 3D measurement volume, area assessment, as well as Left Atrio-Vertebral Ratio¹⁴ in which left atrial area more than three times the vertebral area is highly specific for LAE. Moreover, age and gender-specific thresholds for heart chamber sizes have been described in the recent literature¹⁵. Both AP diameter and axial LA area permit quick and reproducible estimates of LA volume in NEGCT¹⁶. In addition, one article showed a transverse LA diameter of 73 mm had a same sensitivity up to 85% for detecting LA enlargement with an AP diameter of 43 mm¹⁶, whereas in this study, it was 66.7% with an AP diameter of >45 mm.

Our study has few limitations; first, long axis dimensions of the chambers were not included because orthogonal plane reconstructions were not made in routine CT exams. A slight discrepancy existed in this

study for RVE sensitivity, and specificity being 33.33%, 74.86%, as compared to 58.6%, 91.5% in one international study¹²; the phenomenon of RVE overcalling has been observed; reporting false positive cardiac enlargement at CT scan can increase clinicians' as well as patients' anxiety. Another cardiac measurement i.e., LV myocardial thickness for which Yen A *et al.* had reported 91% specificity at NEGCT¹⁸; had not been studied to avoid the complexity of data. This study lack the comparison of echocardiography with ECG gated MRI. Further research needs to be done in this regard.

CONCLUSION

Overall, the accuracy of chamber dimensions at NEGCT was excellent with high CT-Echocardiography concordance, making it an alternative modality for examining chamber sizes, in the absence of cardiac MRI. Through it, a radiologist can also add more value to CT reporting.

REFERENCES

- Gollub MJ, Panu N, Delaney H, Sohn M, Zheng J, Moskowitz CS, Rademaker J, Liu J. Shall we report cardiomegaly at routine computed tomography of the chest? *J Comput Assist Tomogr.* 2012;36(1):67-71.
- Eifer DA, Nguyen ET, Thavendiranathan P, Hanneman K. Diagnostic Accuracy of Sex-Specific Chest CT Measurements Compared With Cardiac MRI Findings in the Assessment of Cardiac Chamber Enlargement. *AJR Am J Roentgenol.* 2018;211(5):993-9.
- Kalisz K, Bueth J, Saboo SS, Abbara S, Halliburton S, Rajiah P. Artifacts at cardiac CT: physics and solutions. *Radiographics.* 2016;36(7):2064-83.
- Krueger M, Cronin P, Sayyouh M, Kelly AM. Significant incidental cardiac disease on thoracic CT: what the general radiologist needs to know. *Insights Imaging.* 2019;10(1):10.
- Chaturvedi A, Thompson JP, Kaproth-Joslin K, Hobbs SK, Schwarz KQ, Krishnamoorthy VK, et al. Identification of Left Ventricle Failure on Pulmonary Artery CTA: Diagnostic Significance of Decreased Aortic & Left Ventricle Enhancement. *Emerg Radiol.* 2017;24(5):487-96.
- Hota Partha, Simpson Scott. Going beyond Cardiomegaly: Evaluation of Cardiac Chamber Enlargement at Non-Electrocardiographically Gated Multidetector CT: Current Techniques, Limitations, and Clinical Implications. 25 Apr, 2019. *RSNA-Cardiothoracic Imaging: VOL. 1, NO. 1.*
- Henz Concatto N., Dowich, M. V., Soldatelli Dorigatti, Pelepenko Teixeira S.I, Da Conceição T. M.B, Silveira A, et al. Measuring cardiac chambers in non-ECG-gated thoracic CT: What the radiologist needs to know (C-1298). Presented at European Congress of Radiology. Mar 4, 2018, 2018. Vienna, Austria.
- Huckleberry J, Haltom S, Issac T, Gabaldon J, Ketai L. Accuracy of non-ECG-gated computed tomography angiography of the chest in assessment of left-sided cardiac chamber enlargement. *J Thorac Imaging* 2012;27:354-8.
- Sverzellati N, Arcadi T, Salvolini L, et al. Under-reporting of cardiovascular findings on chest CT. *Radiol Med (Torino)* 2016;121:190-9.
- Berliner D, Schneider N, Welte T, Bauersachs J. The Differential Diagnosis of Dyspnea. *Dtsch Arztebl Int.* 2016;113(49):834-45.
- Kathiria NN, Devcic Z, Chen JS, Naeger DM, Hope MD, Higgins CB, Ordovas KG. Assessment of Left Ventricular Enlargement at Multidetector Computed Tomography. *J Comput Assist Tomogr.* 2015;39(5):794-6.
- Eifer DA, Nguyen ET, Thavendiranathan P, Hanneman K. Diagnostic Accuracy of Sex-Specific Chest CT Measurements Compared With Cardiac MRI Findings in the Assessment of Cardiac Chamber Enlargement. *AJR Am J Roentgenol.* 2018;211(5):993-9.
- Gürdoğan M, Ustabaşoğlu FE, Kula O, Korkmaz S. Cardiac Magnetic Resonance Imaging and Transthoracic Echocardiography: Investigation of Concordance between the Two Methods for Measurement of the Cardiac Chamber. *Medicina (Kaunas).* 2019;55(6):260.
- Montillet M, Baqué-Juston M, Tasu JP, Bertrand S, Berthier F, Zargane N, et al. The Left Atrio-Vertebral Ratio: a new simple means for assessing left atrial enlargement on Computed Tomography. *Eur Radiol.* 2018;28(3):1310-7.
- Lin FY, Devereux RB, Roman MJ, et al. Cardiac chamber volumes, function, and mass as determined by 64-multidetector row computed tomography: mean values among healthy adults free of hypertension and obesity. *JACC Cardiovasc Imaging* 2008;1:782-6.
- Mahabadi AA, Truong QA, Schlett CL, et al. Axial area and anteroposterior diameter as estimates of left atrial size using computed tomography of the chest: comparison with 3-dimensional volume. *J Cardiovasc Comput Tomogr* 2010;4:49-54.
- Sohrabi S, Hope M, Saloner D, et al. Left atrial transverse diameter on computed tomography angiography can accurately diagnose left atrial enlargement in patients with atrial fibrillation. *J Thorac Imaging* 2015;30:214-7.
- Yen A, Feneis P, Castellanos LR. Detection of concentric left ventricular wall hypertrophy by contrast-enhanced non-electrocardiogram-gated chest computed tomography. *J Cardiovasc Comput Tomogr.* 2017;11(6):482-8.